

# Histopathological Analysis of Focal Infarction in Gerbil Brain Induced by Ferrite Infusion Through the Femoral Vein : New Experimental Model for Focal Infarction

Heasoo Koo

Department of Pathology, College of Medicine, Ewha Womans University

= 국 문 초 록 =

대퇴정맥을 통한 자성체 주입과 두개골에 부착한 자석을 이용한 성숙 Gerbil뇌의 국소경색의 유발 : 조직학적 소견과 국소 뇌허혈 동물모델로서의 이용 가능성

이화여자대학교 의과대학 병리학교실

구 혜 수

목 적 : 허혈성 뇌병변의 실험동물 모델은 임상에서 발병율과 유병율이 높아서 중요한 질환인 뇌혈관질환의 병태생리학적 기전, 예방, 치료의 연구에 중요한 역할을 한다. 국소허혈병변은 대부분의 연구에서 쥐 또는 고양이의 중뇌동맥 폐쇄법이나 gerbil의 일측 경동맥 폐쇄법이 가장 널리 이용되고 있다. 그러나 이런 방법들은 수술기법이 단순하지 않고 허혈 병변부위나 범위가 일정하지 않아 원하는 부위에 원하는 크기의 일정한 병변을 유발하기가 용이하지 않았다. 근래에 두개골 표면에 강력 소자석을 부착하고 미세한 자성체 입자를 혈중으로 투여하여 국소 뇌허혈병변을 유발하는 방법이 고안되었다. 본 연구는 이 방법에 의해 발생하는 뇌허혈 병변의 시간에 따른 병리조직학적 소견을 분석하여 앞으로의 실험에 이용할 수 있는 기초로 하기 위하여 시행되었다.

방 법 : 성숙 gerbil(50-70 gm)의 두피를 박리후 측두부 혹은 전두부의 두개골 표면에 직경 7 mm, 두께 2 mm의 자석(표면자장 강도 2,000-2,400 Gauss)을 접착고정하고 대퇴정맥에 삽입된 소관을 통해 특수처리된 산화철 입자( $\gamma$ -Fe $_2$ O $_3$ , 0.2 $\times$ 0.02  $\mu$ m)의 생리 식염수 현탁액을 주입하였다. 투여후 1, 2, 6 시간과 1, 2, 3, 7, 8, 10, 14 일 후에 조직학적 소견을 관찰하였다.

결 과 : 국소허혈병변인 뇌경색은 총 59예중 51예에서 발생하였고 전두엽과 두정엽의 대뇌 피질에 가장 흔히 관찰되었으며, 해마, 시상, 기저핵에서도 관찰되었다. 19예에서 작은 경색이 몇개씩 보였으며 32예에서는 큰 경색이 여러개 보였다. 9예에서 반대편 대뇌피질에 작은 경색이 동반되었다. 산화철 입자는 경색 주변이나 뇌막의 혈관에서 관찰되었고 경색의 조직학적 소견은 비교적 전형적인 변화의 진행을 보였다.

결 론 : 본 실험방법을 자석의 강도나 산화철입자의 크기, 실험동물의 조건을 일정하게 유지하여 시행한다면 원하는 위치에 원하는 크기의 경색을 비교적 간단한 방법으로 유발할 수 있어서 앞으로 색전에 의한 뇌경색의 연구에 이용할 수 있다고 사료된다.

## Introduction

Physiologically regulated reproducible animal models of brain ischemia or infarction are crucial for pathophysiological study and evaluation of treatment. In rodents, global cerebral ischemia can be induced by transient bilateral common carotid artery (CCA) occlusions plus hypotension<sup>1,2)</sup> or four-vessel occlusion (bilateral CCA occlusions plus permanent vertebral artery occlusions)<sup>3,4)</sup>. Transient global ischemia models showed well documented selective neuronal damage within vulnerable brain regions, such as hippocampus and deep layer of cortex. Focal cerebral ischemia have been experimentally induced by middle cerebral artery (MCA) occlusion, stroke in hypertensive rat, photochemically induced focal cerebral thrombosis, and miscellaneous methods causing cerebral embolism and thrombosis such as blood clot or microsphere embolization, photochemically initiated thromboembolism, and arachidonate-induced thrombosis. Models of focal ischemia (with or without reperfusion) usually cause localized pannecrosis or infarction<sup>5,6)</sup> and the location depends on experimental method and level of ligation.

Because of poor development of circle of Willis, unilateral and bilateral cerebral ischemia can be produced in gerbils by occluding one or both CCAs. Bilateral CCA occlusion in gerbils results in residual blood flow even below 5.0 ml/100 gm/min in wide areas as early as 3 minutes and showed typical sequential damages in hippocampal neurons depending on duration of ischemia, with or without reperfusion, and anatomical regions (global cerebral ischemia)<sup>7-9)</sup>.

Recently, a new focal cerebral infarction model was proposed in gerbil, which was induced by infusion of ferrite through femoral vein and magnetite attachment on skull (personal communication). The method was quite simple compared to previous experimental models, but the incidence and location of infarcts in this model have not been well known, yet. In this study, I carefully evaluated the incidence and location of infarct as well as histopathological findings

at different times from 1 hour to 14 days in that experimental model to see the further possibility for studies on ischemic encephalopathy.

## Material and Methods

### 1. Production of focal infarction of brain

Mongolian gerbils (*Meriones unguiculatus*) of both sexes weighing 50–70 gm were used for the present study. Each gerbil was allowed free access to food and water before and after surgery. Focal ischemia was induced in 59 gerbils as follows. Under ketamine anesthesia, incision of scalp skin was made and a round magnetite of 2 mm thickness and 7 mm diameter (surface magnetic power of 2,000–2,400 Gauss) was attached on right parietal bone by glue. Right femoral vein was exposed and ferrite ( $\gamma$ -Fe<sub>2</sub>O<sub>3</sub>, 0.2 × 0.02 μm) mixed in saline solution were infused through rubber catheter (0.67 mg/100 gm of body weight). One to 11 gerbils were examined after 1, 2, or 6 hours and 1, 2, 3, 7, 8, 10, or 14 days (Table 1). The rectal temperature of the gerbils was maintained at 36°C using a heating pad and a heating lamp during the procedure. At least 2 control rats were included in each group, which were treated ferrite infusion without magnetite attachment or sham-operated without ferrite infusion or magnetite attachment.

### 2. Tissue preparation

At the scheduled time, each gerbil was anesthetized and the brain was fixed with transcardiac infusion of 4% paraformaldehyde following perfusion with isotonic saline to remove blood from the cerebral vasculature. The brains were removed and fixed in the same solution for a further 24 hours. Coronal sections of the supratentorial portion of each brain were taken and embedded in paraffin. Routine sections were stained with hematoxylin-eosin (H-E) and incidence and location of infarctions was analyzed as well as histopathological findings according to the time. Infarctions were graded 0=normal, 1+=less than 10% of total volume was infarcted, 2+=10–40% of total volume was infarcted, and 3+=more than 50% of total volume was infarcted.

**Table 1.** Incidence and location of infarct at various times after ferrite infusion

Time	Rat No	FP		Hippo		Thal		Caud		Oppo	
		1+	2-3+	1+	2-3+	1+	2-3+	1+	2-3+	1+	2-3+
1 hr	1	1	0	0	0	0	0	0	0	0	0
2 hrs	2	1	0	0	0	0	0	0	0	0	0
6 hrs	2	1	0	0	0	0	0	0	0	0	0
1 day	5	1	3	1	2	2	0	1	0	2	0
2 days	3	3	0	0	0	0	0	0	0	0	0
3 days	9	2	7	2	5	2	0	2	0	0	0
7 days	5	1	1	0	1	1	0	0	0	0	0
8 days	11	4	7	3	5	1	3	5	0	3	0
10 days	11	2	7	5	6	6	1	2	0	3	0
14 days	10	5	2	1	4	0	1	1	0	1	0
Total	59	21	27	12	23	12	5	11	0	9	0

No : number

FP : frontoparietal cortex

Hippo : hippocampus

Thal : thalamus

Caud : caudate

Oppo : opposite side

1+ : less than 10% of total volume

2+ : 10 - 40% of total volume

3+ : more than 40% of total volume

## Results

The sham-operated control rats without ferrite infusion or magnetite attachment and control rats with ferrite infusion only did not show any histopathological changes.

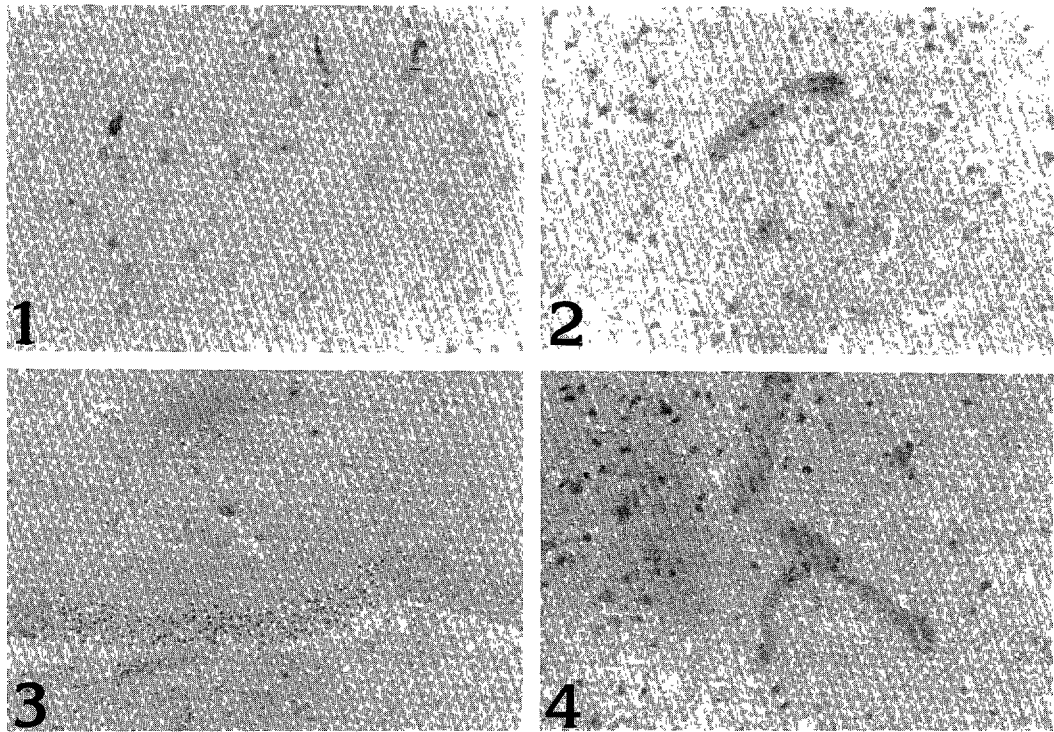
Infusion of iron powder through femoral vein showed plugging of powder in small blood vessels in meninges as well as in brain parenchyme with resultant focal infarcts, which were well documented in our previous studies(data not shown). Although the size and location of infarcts were quite variable in this experimental model, changes in and around the infarcts were similar depending on the time after the injury.

The histopathological findings in experimental group are summarized in Table 1. 51 out of total 59 rats(86.4%) showed variable degree of focal infarction involving frontoparietal cortex, hippocampus, thalamus, and caudate nucleus. The frontoparietal cortex was most commonly involved(48 out of 51 rats with infarcts, 81.4%), followed by hippocampus(35 rats, 59.3%), thalamus(17 rats, 20.8%), and caudate nucleus (11 rats, 10.6%). 9 rats(15.3%) showed small focal infarcts in cortex of contralateral side. 19 rats(37.3%) showed one or several small infarct(s) and 32(62.7%) showed large single or multiple infarcts.

At 1 and 2 hours, focal infarct was manifested as a localized palor of neuropil with not much changes of neurons(Fig. 1). At 6 hours, the infarct showed palor of neuropil with eosinophilic neurons and leukocytes margination at blood vessels(Fig. 2). At 1 day, palor and eosinophilic neurons were more advanced with necrosis of vascular wall and hemorrhage(Fig. 3). At 2 days, macrophages started to show up and vascular wall necrosis was prominent with extravasation of leukocytes(Fig. 4). At 3 days, infarcted areas showed fragmentation of tissue with loss of cells and increased numbers of macrophages. At 7 days, the macrophages and blood vessels were filled in necrotic areas and vascular wall necrosis as well as hemorrhages were also noted(Figs. 5 & 6). 3 rats with no infarcts or ferrite emboli showed unilateral multifocal pale areas in cortex and basal ganglia. At 8 days, the infarcts showed central necrosis and accumulation of macrophages at the periphery(Fig. 7). At 10 and 14 days, blood vessels were increased compared to macrophages in infarcts with decreased tissue volume, and in other areas, the necrotic areas were filled with macrophages(Fig. 8).

## Discussion

The method used in this study was less invasive and simpler with good survival rate than previously de-



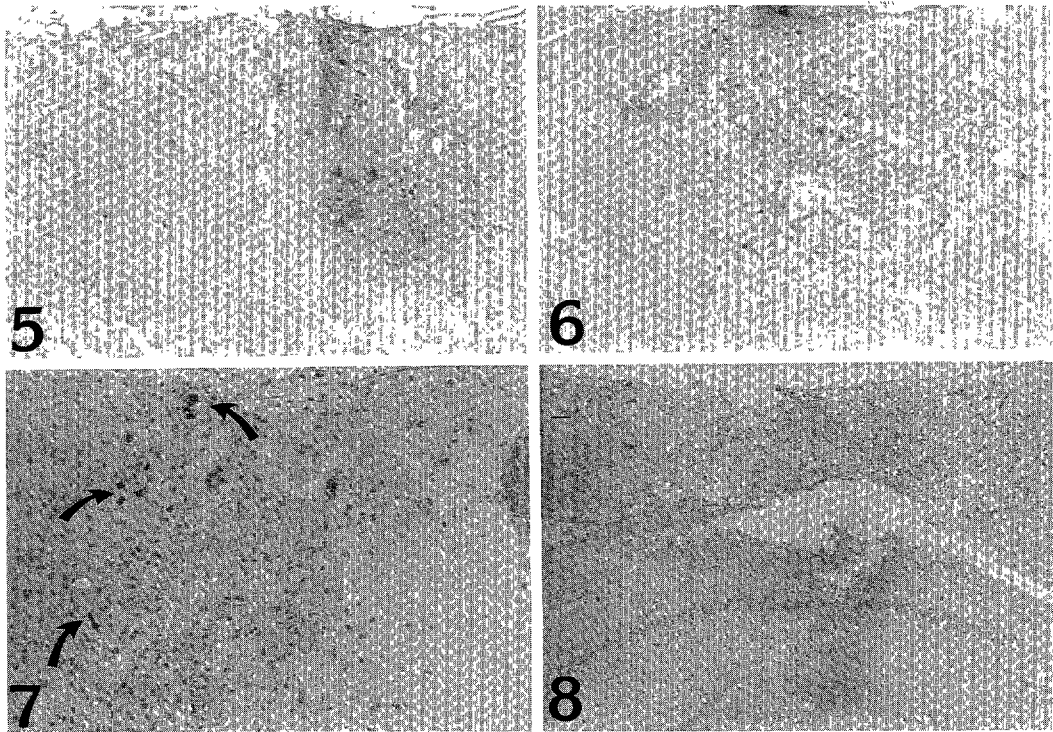
**Fig. 1.** Palor of neuropil with perineuronal edema at 2 hours (H-E,  $\times 100$ ).  
**Fig. 2.** Palor and vacuolization of neuropil with eosinophilic neurons and leukocyte margination on inner surface of blood vessel at 6 hours (H-E,  $\times 100$ ).  
**Fig. 3.** Focal infarct involving dentate gyrus of hippocampus at 1 day-Vascular walls are necrotic with vacuolization of neuropil (H-E,  $\times 50$ ).  
**Fig. 4.** Necrosis of vascular wall with extravasation of leukocytes and infiltration of macrophages at 2 days (H-E,  $\times 100$ ).

veloped focal ischemia models, which was considered as one of the advantages of this method. Some gerbils died suddenly after ferrite infusion, which was most likely due to pulmonary infarcts.

The incidence of focal infarct by this method was 86.4% (51 out of 59 rats) and the frontoparietal cortex was most commonly involved (81.4%, 48 rats) and hippocampus was involved in 59.3%. 19 (37.3%) out of 51 rats with infarction showed one or several small infarcts (1+) compared to 32 (62.7%) of large single or multiple infarcts (2-3+). Thalamus and caudoputamen were also involved in 17 (20.8%) and 11 rats (10.6%), respectively. In addition, 9 (15.3%) rats showed additional small infarcts in contralateral frontoparietal cortex. The difference in size and location was probably due to difference in magnetite and ferrite as well as difference in animals. Further study

with well controlled variables will be necessary to get uniform size of infarcts at certain region of the brain, which are necessary in experimental conditions. In addition, physiological conditions and blood flow changes should be standardized and controlled.

The lesion induced by this method was a permanent occlusive focal infarction similar to embolic infarcts in clinical conditions. The changes of blood vessels and leukocyte margination at 6 hours and extravasation of leukocytes at 2 days were quite typical in early stage of infarction and suggested the possibility of using this method in studies on endothelial cell injury and leukocytes adhesion. The changes of infarcts followed typical sequential steps according to the age of the infarcts, such as first appearance of macrophages at 2 days and developing necrosis in the center surrounded by macrophages and many small



**Fig. 5.** Central necrotic area surrounded by blood vessels and macrophages at 7 days (H-E,  $\times 50$ ).

**Fig. 6.** Infarct involving thalamus at 7 days – Necrosis and hemorrhage with many macrophages (H-E,  $\times 50$ ).

**Fig. 7.** Central necrosis and prominent blood vessels at periphery at 8 days-Ferrite emboli are scattered(Arrows) (H-E,  $\times 50$ ).

**Fig. 8.** Infarct involving cortex and hippocampus at 10 days-Decreased tissue volume with diffuse replacement of necrotic areas by macrophages (H-E,  $\times 20$ ).

blood vessels at the periphery at 7 days and decreased brain volume at 10 and 14 days. Studies on local effects and changes of focal infarcts could be done by this method. The advantages of this method are simple procedure with good survival and the possibility to place an infarct in any chosen location by controlling the size and attached site of magnetite. Disadvantage of this method is its end-arterial occlusive nature, that makes the lesion resistant to therapies.

Among focal ischemic encephalopathy models, rat models of MCA occlusion have been commonly used in studies and the location and size of the infarcts were quite different according to the methods<sup>10-17</sup>. Subtemporal approach of Tamura et al<sup>10,11</sup>, has been a standard method of proximal MCA ligation, which showed infarctions involving both cortex and caudoputamen. Bederson et al<sup>13</sup>, achieved consistent in-

farct by isolating lenticulostriate arteries and small cortical branches from both proximal and distal sources of collateral blood supply. In Sprague-Dawley rats, occlusion of MCA by electrocoagulation proximal to the origins of the lateral lenticulostriate arteries showed mean cerebral blood flow(CBF) of 25 ml/100 g/min. Chen et al<sup>14</sup>, developed a surgically less demanding, more distal occlusion of the MCA above the rhinal fissure coupled with permanent ipsilateral and temporary contralateral CCA occlusions. CBF was reduced to 18% of control and protracted survival was possible. The brain showed moderate sized infarcts in frontoparietal cortex, sparing caudoputamen. Duverger and MacKenzie<sup>18</sup> studied the sequelae of permanent MCA occlusion in several strains, which showed difference according to the animal strains. All strains showed infarcts in the caudoputamen and olfactory

cortex was most consistently infarcted with more variable involvement of frontoparietal somatosensory cortex. Mean infarct volume was smallest and most variable in Wista-Kyoto rats, larger and more consistent in Sprague-Dawley rats, and largest and most consistent in Fischer-344 rats. The spontaneous hypertensive rat(SHR) and stroke-prone spontaneously hypertensive rat(SHRSP) strains showed hemispheric infarct volume of 1.5–1.6 times compared to Fischer-344 rats.

Temporary MCA occlusion can be achieved by photochemical method, in which thrombosis is induced in a MCA segment by laser illumination following systemic administration of rose bengal<sup>17,19-21)</sup>. The occlusive thrombosis is composed of aggregated erythrocytes and platelets and prompt recanalization is achieved by topical application of nimodipine to the occluded segment. One hour after recanalization, the striatum showed mixed pattern of infarction and ischemic cell changes compared to largely preserved neocortex. Size and depth of the lesion depend upon the intensity of the irradiating beam, the duration of irradiation, and the dose of rose bengal administered and the infarct may be placed in any desired cortical location. Microvascular perfusion failure is evident within minutes and the lesion doubles in size during the first 4 hours<sup>20)</sup>. The present study also showed the earliest changes at 1 hour and changes could be detected at earlier time if the examination were done. The advantages of photochemical model are minimally invasive procedure permitting chronic animal survival, consistent lesion size, the ability to place an infarct in any chosen cortical location, and the involvement of endothelial injury and platelets aggregation, conveying the potential for this model to be used in studies of antiplatelet or thrombolytic therapy.

In conclusion, the present study showed this rodent model of focal cerebral ischemia could be used in studies investigating mechanisms, preventions, and treatment of ischemic brain injury. In addition, application of biochemical, physiologic, or behavioral methods to this model would be necessary.

## References

- 1) Eklöf B, Siesjö BK : *The effect of bilateral carotid artery ligation upon the blood flow and energy state of the rat brain. Acta Physiol Scand* 1972 : 86 : 155-165
- 2) Nordström C-H, Siesjö BK : *Effects of phenobarbital in cerebral ischemia. Part I : Cerebral energy metabolism during pronounced incomplete ischemia. Stroke* 1987 : 327-335
- 3) Pulsinelli WA, Brierley JB : *A new model of bilateral hemispheric ischemia in the unanesthetized rat. Stroke* 1979 : 10 : 267-272
- 4) Pulsinelli WA, Buchan AM : *The four-vessel occlusion rat model : Method for complete occlusion of vertebral arteries and control of collateral circulation. Stroke* 1988 : 19 : 913-914
- 5) Graham DI : *Hypoxia and vascular disorders. In : Adams JH, DuChen LW, eds. Greenfield's Neuropathology. ed 5. London Melbourne Auckland : Edward Arnold, 1992 : 153-268*
- 6) Ginsberg MD, Busto R : *Rodent models of cerebral ischemia. Stroke* 1989 : 20 : 1627-1642
- 7) Suzuki R, Yamaguchi T, Kirino T, Orzi F, Klazo I : *The effects of 5-min ischemia in Mongolian gerbils : 1. Blood-brain barrier, cerebral blood flow, and local cerebral glucose utilization changes. Acta Neuropathol(Berl)* 1983 : 60 : 207-216
- 8) Yoshimine T, Morimoto K, Brengman JM, Homburger HA, Mogami H, Yanagihara T : *Immunohistochemical investigation of cerebral ischemia during recirculation. J Neurosurg* 1985 : 63 : 922-928
- 9) Hatakeyama T, Matsumoto M, Brengman JM, Yanagihara T : *Immunohistochemical investigation of ischemic and postischemic damage after bilateral carotid occlusion in gerbils. Stroke* 1988 : 19 : 1526-1534
- 10) Tamura A, Graham DI, McCulloch J, Teasdale GM : *Focal cerebral ischaemia in the rat : 1. Description of technique and early neuropathological consequences following middle cerebral artery occlusion. J Cereb Blood Flow Metab* 1981 : 1 : 53-60
- 11) Tamura A, Graham DI, McCulloch J, Teasdale

- GM : *Focal cerebral ischemia in the rat : 2. Regional cerebral blood flow determined by (<sup>14</sup>C) iodoantipyrine autoradiography following middle cerebral artery occlusion. J Cereb blood flow Metab 1981 : 1 : 61-69*
- 12) Mohamed AA, Gotoh O, Graham DI, Osborne KA, McCulloch J, Mendelow AD, Teasdale GM, Harper AM : *Effect of pretreatment with the calcium antagonist nimodipine on local cerebral blood flow and histopathology after middle cerebral artery occlusion. Ann Neurol 1985 : 18 : 705-711*
  - 13) Bederson JB, Pitts LH, Tsuji M, Nishimura MC, Davis RL, Bartkowski H : *Rat middle cerebral artery occlusion : Evaluation of the model and development of a neurologic examination. Stroke 1986 : 17 : 472-476*
  - 14) Chen ST, Hsu CY, Hogan EL, Maricq H, Balentine JD : *A model of focal ischemic stroke in the rat : Reproducible extensive cortical infarction. Stroke 1986 : 17 : 738-743*
  - 15) Gotoh O, Mohamed AA, McCulloch J, Graham DI, Harper AM, Teasdale GM : *Nimodipine and the haemodynamic and histopathological consequences of middle cerebral artery occlusion in the rat. J Cereb Blood Flow Metab 1986 : 6 : 321-331*
  - 16) Osborne KA, Shigeno T, Balarsky AM, Ford I, McCulloch J, Teasdale GM, Graham DI : *Quantitative assessment of early brain damage in rat model of focal cerebral ischaemia. J Neurol Neurosurg Psychiatry 1987 : 50 : 402-410*
  - 17) Prado R, Ginsberg MD, Dietrich WD, Watson BD, Busto R : *Hyperglycemia increases infarct size in collaterally perfused but not end-arterial vascular territories. J Cereb Blood Flow Metab 1988 : 8 : 186-192*
  - 18) Duverger D, MacKenzie ET : *The quantification of cerebral infarction following focal ischemia in the rat : Influence of strain, arterial pressure, blood glucose concentration, and age. J Cereb Blood Flow Metab 1988 : 8 : 449-461*
  - 19) Rosenblum WL, El-Sabban F : *Platelet aggregation in the microcirculation. Effect of aspirin and other agents. Stroke 1977 : 40 : 320-328*
  - 20) Watson BD, Dietrich WD, Busto R, Wachtel MS, Ginsberg MD : *Induction of reproducible brain infarction by photochemically initiated thrombosis. Ann Neurol 1985 : 17 : 497-504*
  - 21) Nakayama H, Dietrich WD, Watson BD, Busto R, Ginsberg MD : *Photothrombotic occlusion of rat middle cerebral artery : Histopathological and hemodynamic sequelae of acute recanalization. J Cereb Blood Flow Metab 1988 : 8 : 357-366*