

Cerebrovascular Complications of Rhinocerebral Mucormycosis

Yong-Jae Kim · Kee-Duck Park · Kyoung-Gyu Choi · Hea-Soo Koo*

Department of Neurology & Pathology,* College of Medicine and Ewha Medical Research Center,
Ewha Womans University

= 국문 초록 =

두부 모균증의 뇌혈관 합병증

이화여자대학교 의과대학 의과학연구소, 신경과학교실, 병리학교실*

김용재 · 박기덕 · 최경규 · 구혜수*

모균증은 진균 감염증의 하나로 급성으로 진행되며 사망률이 높은 질환이다. 다양한 임상 양상으로 나타나며 두부 모균증이 가장 흔한 형태이다. 두부 모균증의 임상 경과와는 감염의 해부학적 위치에 따라 두통, 안면 부종, 압통부터 안구 돌출, 안구 마비, 시력 소실 등 다양하게 나타난다. 모균증은 혈관계를 잘 침범하며, 두부 모균증의 경우 해면 정맥동의 침범뿐 아니라 아주 드물게 내 경동맥이나 두강 내 혈관을 침범하는 경우도 있다. 저자들은 뇌혈관 질환이 동반된 두부 모균증의 드문 합병증 3예를 경험하였기에 문헌 고찰과 함께 보고하는 바이다.

중심 단어 : 두부 모균증 · 합병증 · 뇌혈관 질환.

Introduction

Mucormycosis is a highly aggressive fungal infection that usually occurs in debilitated patients with an underlying pathologic condition. It can present in different clinical forms, the most common being rhinocerebral mucormycosis (RCM). Personal experience with three cases of rhinocerebral form of mucormycosis with occlusive vasculitis and cerebral infarction is the basis of this report. In this report, we will present two cases with vascular invasion of orbital and intracranial arteries in detail, and summarize our clinical experience with additional case of RCM with occlusive vasculitis and cerebral infarction.

This form of disease typically starts in the nose, paranasal sinuses, or orbits, producing nasal discharge and crusting, proptosis, ophthalmoplegia, and visual loss. The association of CNS involvement has been well documented. In such cases, most striking and unusual feature is the marked propensity of the hyphae to invade the walls and lumens of blood vessels.

Patients & Methods

Three patients with rhinocerebral mucormycosis with occlusive vasculitis and cerebral infarction were diagnosed and treated at Ewha Womans University Mokdong hospital, Ewha Womans University hospital and Catholic university St. Mary's hospital, between the years 1990

and 2000. Data regarding these patients including age, sex, systemic diseases, signs, symptoms, location, radiological findings, treatment, and survival, were retrieved from the patients' hospital medical records. The diagnosis in case was based on pathological examination.

Case 1 :

A 43-year-old male, diabetic, well controlled on oral hypoglycemic agents, experienced sudden onset left orbital pain and visual loss. He had suffered from generalized malaise associated with rhinorrhea, fever, and retro-orbital pain. On examination, the patient was alert and coherent. His body temperature was 37.2C. His neck was supple, and neurologic examination disclosed no motor deficits, gross paresthesia, or ataxia. Cranial nerves, except for the left second nerve, were normal on examination. Ocular examination disclosed visual acuity of light perception OS and 20/25 OD. There was a left afferent pupillary defect. Confrontational visual fields were full on the right. Ocular versions were full in both eyes. He had no proptosis. Examination of left fundus revealed pale optic disc with diffuse retinal edema consistent with an occlusion of the central retinal artery; the right fundus was normal.

Laboratory data included a white blood cell count 10,400/cu mm with left shift, ESR 99mm/hr, blood sugar 369mg/100mL without ketones and an absence of anemia or acidosis. CT scanning revealed opacification of the left ethmoid air cells without retro orbital abnormalities. The cavernous sinuses were unremarkable. Results of otorhinolaryngologic examination showed necrosis of the left middle turbinate. He was treated with broad spectrum antibiotics and taken emergently to the operating room for presumed mucormycosis. The patient underwent surgery for radical sinus debridement. Black necrotic eschar filling the sinuses was removed. Histopathologic examination of the necrotic tissue revealed the characteristic nonseptate branching hyphae of mucormycosis (Fig. 1). The patient was maintained on daily infusion of amphotericin B therapy along with local paranasal debridement and packing. A daily regimen of intravenous amphotericin B 1mg/kg/day was continued for 30 days, and then on alternate days for another 30 days. Strict control of his blood sugar was maintained.

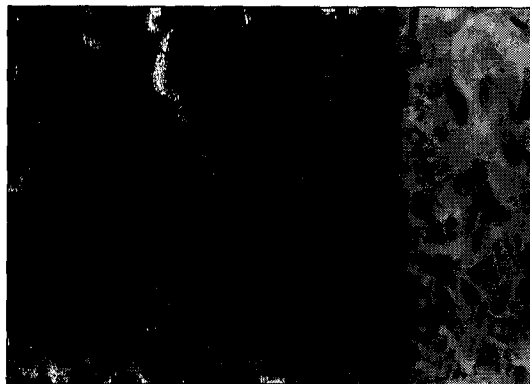


Fig. 1. Biopsy specimen of paranasal sinus with PAS stain ; large nonseptate hyphae with right angle branch.

Four weeks after later, the left eye remained near blind but the pain had decreased. Fluorescein angiography of the left eye showed marked delay in retinal arterial perfusion (retinal arterial filling had still not occurred at the time of venous flow in the contra lateral eye), the optic disc was nonperfused. Six months later, the patient was blind in the left eye but otherwise asymptomatic.

Case 2 :

A 62-year-old male, diabetic was admitted to the hospital because of painful swelling of the right eye and a decrease in vision. He was doing well until two weeks prior to admission when he noted frontal headaches on the right side followed by gradually decreasing vision in the right eye and pain, redness, and swelling in the right periorbital area.

Examination on admission revealed a drowsy man. The right eye was markedly swollen with ecchymosis of the eyelids, ptosis, and mild proptosis. The pupil was fixed dilated with no perception of light. There was complete external ophthalmoplegia with absent corneal reflex and loss of sensation along the distribution of the trigeminal nerve on the right. Examination of the left eye yielded normal results. Systemic neurologic examination disclosed no other motor deficits, gross paresthesia, or ataxia. An ophthalmologist was consulted and made the diagnosis of cavernous sinus hemorrhage and central retinal artery occlusion.

Laboratory data on admission revealed a hematocrit of 29.1%, WBC count of 13,400/100ml (90% neutrop-

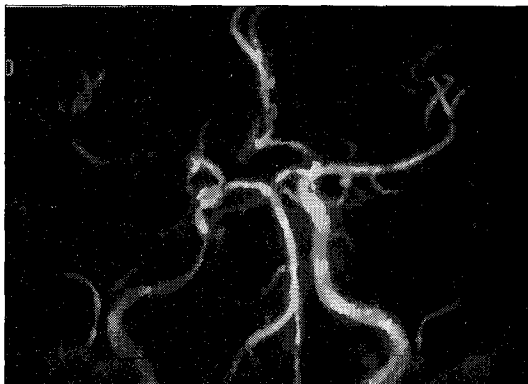


Fig. 2. MRA shows multi-segmental stenosis.

hils). Blood sugar of 235mg/100ml without ketone. Arterial blood gases showed no acidosis. A CT scan of the orbit showed maxillary, ethmoid and sphenoid opacity without mass lesion in orbit. Otolaryngology consultation was requested. The palate was normal but the nasal septum was black and necrotic. The necrotic septum was biopsied and microscopic examination revealed characteristic broad non-septate hyphae. Amphotericin B was started. Four weeks after admission, the patient suddenly became stuporous. The cranial nerve findings were unchanged but he had a flaccid left hemiparesis. Brain MR images showed multiple, high signal intensity lesions at the area of right centrum semiovale and multifocal disruption of luminal flow signal in M1, M2 portion of right MCA (Fig. 2). This was thought to represent propagation of mycotic thrombus down the vessel wall. Three months later, the patient was blind in the right eye and gait with stick due to his left hemiparesis.

Case 3 :

A 57-year-old male, diabetic was admitted to the hospital because of painful swelling of the right eye and blindness. He was doing well until two weeks prior to admission when he noted frontal headaches on the right side followed by gradually decreasing vision in the right eye and pain, redness, and swelling in the right periorbital area.

Examination on admission revealed a markedly swollen with ecchymosis of the eyelids ptosis on his right eye. The pupil was fixed dilated with no perception of light. There was complete external ophthalmoplegia with absent

corneal reflex and loss of sensation along the distribution of the trigeminal nerve on the right. Examination of the left eye was normal. Systemic neurologic examination disclosed no other abnormalities.

WBC count was 13,400/100ml with left shift. Blood sugar of 235mg/100ml without ketone. A CT scan of the PNS showed maxillary, ethmoid and sphenoid opacity without mass lesion in orbit. The necrotic mass in sinuses was biopsied under Combi operation and microscopic examination revealed characteristic broad non-septate hyphae. A clinical diagnosis of RCM was made and amphotericin B was started. A week after admission, the patient suddenly became drowsy and had a flaccid right hemiparesis. These were nearly full recovered within 30 minutes. Brain MRI showed lesions at the area of left basal ganglia. Cerebral angiography showed occlusion of the left ophthalmic artery and stenosis of the left middle cerebral artery. This was thought to represent intracranial involvement. Six months later, the patient was blind in the right eye. But the ptosis was on improving state and there was no more TIA.

Discussion

Mucormycosis is a term used to describe infections caused by fungi of the order Mucorales. These fungi are common and are not ordinarily pathogenic. The most common predisposing feature of clinical infection is poorly controlled diabetes mellitus, particularly ketoacidosis¹⁾. All our patients had diabetes mellitus, but without ketoacidosis when infected. Other predisposing factors include leukemia, lymphoma, immunosuppression and burns²⁾³⁾. It can present in different clinical forms, the most common being RCM. This form typically begins in the nose and paranasal sinuses. The fungus has a marked propensity to invade blood vessels⁴⁾⁵⁾. Arterial thrombosis may give a characteristic black necrotic lesion in the nose or on the palate from which the histological diagnosis may be made by the appearance of nonseptate hyphae. Infection, then, usually involves the orbit. The most frequent clinical manifestation of RCM are headache and swelling of the fronto-orbital area, intranasal necrosis, decreased vision, and ophthalmoplegia²⁾³⁾. Two of our cases (cases 2, 3) were typical in these respects. But in

case 1, we could not find any external and internal ophthalmoplegia. In this rare case, involvement of the central retinal artery produced blindness without ophthalmoplegia. Several routes exist for further extension, such as cribriform plate or retrograde to the apex of the orbit involving the ophthalmic artery, internal carotid artery, and cavernous sinus. Occlusions in both large and small vessels result³⁻⁵⁾. The change in brain may be a result of direct invasion and necrosis or infarction caused by vessel occlusion.

Prognosis is poor, and therapeutic success usually involves a combination of radical surgery and aggressive medical therapy. All our patients were treated with intravenous amphotericin B therapy, resulted in relatively good prognosis.

The primary differential diagnosis includes infection by another fungus, *Aspergillus*. This fungus has a similar predisposition for invading and occluding arteries, but the clinical course is usually less acute than that of mucormycosis⁶⁾⁷⁾. Entities that may cause similar findings in the orbit or paranasal sinuses, such as Wegener's granulomatosis, polymorphic reticulosis, sarcoidosis, and bacterial infection, would not be expected to cause major arterial disease³⁾⁸⁾⁹⁾.

Mucormycosis is a treatable disease. Based on our experience with these 3 cases, we wish to emphasize the importance of early diagnosis of RCM in orbital infarction syndrome. Though it is very rare in clinical practice, vascular involvement should be considered in case of RCM. This can be made only by a high suspicion in the presence of a typical clinical setting with confirmation

by biopsy.

References

- 1) Abramson W, Wilson D, Arky D : *Rhinocerebral phycomycosis in association with diabetic ketoacidosis : Report of two cases and a review of clinical and experimental experience with amphotericin B therapy. Ann Intern Med* 1967 ; 66 : 735-742
- 2) Pillsbury HC, Fisher ND : *Rhinocerebral mucormycosis. Arch Otolaryngol* 1977 ; 103 : 600-604
- 3) Parfrey NA : *Improved Diagnosis and prognosis of mucormycosis. Medicine* 1986 ; 65 : 113-123
- 4) Lowe JT, Hudson WR : *Rhinocerebral phycomycosis and internal carotid artery thrombosis. Arch Otolaryngol* 1975 ; 101 : 100-103
- 5) Anaissie EJ, Shikhani AH : *Rhinocerebral mucormycosis with internal carotid occlusion : Report of two cases and review of the literature. Laryngoscope* 1985 ; 95 : 1107-1113
- 6) Grossman RI, Davis KR, Taveras JM, Beal MF, O'Carroll CP : *Computed tomography of intracranial aspergillosis. J Comput Assist Tomogr* 1981 ; 5 : 646-650
- 7) Dorzbach RK, Segrest DR : *Orbital aspergillosis. Ophthalmic Surg* 1983 ; 14 : 240-244
- 8) Vermess M, Haynes BF, Fauci AS, Wolff SM : *Computer assisted tomography of orbital lesion in Wegener's granulomatosis. J Comput Assist Tomogr* 1978 ; 2 : 45-48
- 9) Wolk RB : *Sarcoidosis of the orbit with bone destruction. AJNR* 1984 ; 5 : 204-205