

Syndrome of Progressive Bulbar Palsy in Amyotrophic Lateral Sclerosis

— A Case Report —

Kyu Man Shin, M.D., and Sun Ho Chee, M.D., D.M. Sc.

Department of Neurological Surgery, College of Medicine, Ewha Womans University

= 國文抄錄 =

進行性 延髓麻痺 症候群 1例

梨花女子大學校 醫科大學 神經外科學教室

辛 圭 萬·池 善 豪

著者들은 43歲 女子患者에서 延髓의 筋萎縮性 側索硬化症으로 發生된 進行性 延髓麻痺 症候群 1例를 報告하는 바이다.

The authors describe a case of syndrome of progressive bulbar palsy in amyotrophic lateral sclerosis which was diagnosed by electromyography.

Key Words · *Amyotrophic lateral sclerosis* · *Syndrome of progressive bulbar palsy* · *Electromyography*.

Amyotrophic lateral sclerosis(ALS), first described by Charcot and Joffroy⁵⁾ in 1869, is a chronic progressive disease of unknown etiology which is characterized by atrophy and fibrillation of the somatic musculatures as result of degeneration of motor cells in the spinal cord and medulla oblongata.

It afflicts men two to three times as often as it does women and begins usually between the ages of 40 and 70^{10) 16) 18) 21)}.

The term "syndrome of progressive bulbar palsy" is applied to the group of the patients who present with wasting of the bulbar muscles, particularly of the tongue at an early stage in the disease. In these cases the disease runs eighteen months from the onset of sym-

ptoms^{10) 16) 18) 21)}.

Authors have presented a case of syndrome of progressive bulbar palsy in amyotrophic lateral sclerosis which diagnosed by electromyography (EMG).

Case Report

History: A 43-year-old woman who was seen in November 1979, complaining of dysarthria and dysphagia of 9 months' duration, with subsequent development of weakness of the bulbar musculatures. She had no past history of nervous disease or of any serious illness, and none of her family had a history of neuromuscular disease.

Examination: Abnormal clinical findings were limited to the neuromuscular system. The tongue was atrophic and she could not be totally unable to produce it from the mouth(Fig. 1). Movements of the palate was weak and the gag reflex was deminished. Her speech was monotonous and deglutition was impaired. Weakness or atropy of shoulder girdle and sternocleidomastoid muscles of the right side were pronouced(Fig. 2). The deep tendon reflexes were hyperactive. The Babinski sign

was not present but Hoffman's sign was present in the right side. Results of lumbar puncture were within normal values. EMG of the tongue revealed normal conduction velocity but showed widespread denervation patterns with fibrillations(Fig. 3). EMG of the sternocleidomastoid muscle of the right side showed denervation potentials and polyphasic potentials(Fig. 4). But normal findings were revealed in EMG study of C5 cord down.

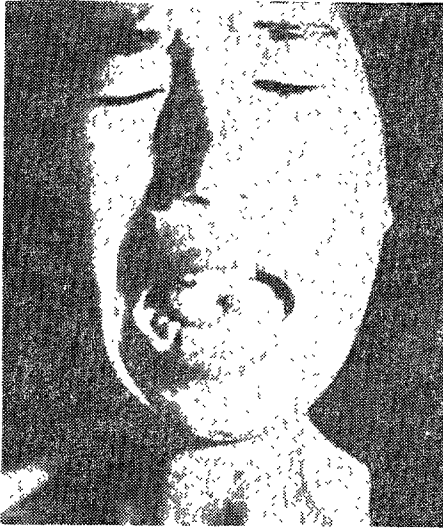

Fig. 1. This photograph shows that the patient is totally unable to her tongue from the mouth.

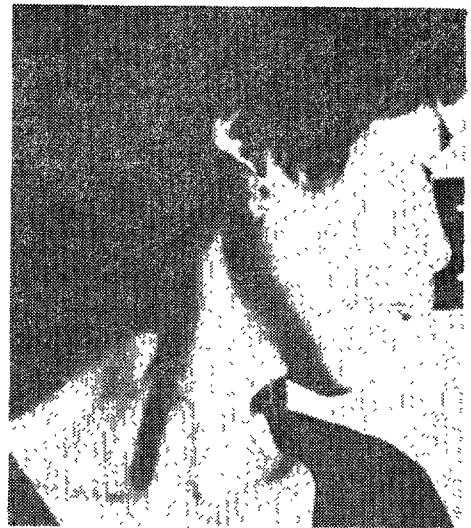

Fig. 2. This photograph shows atrophy of sternocleidomastoid muscle of the right side of this patient.

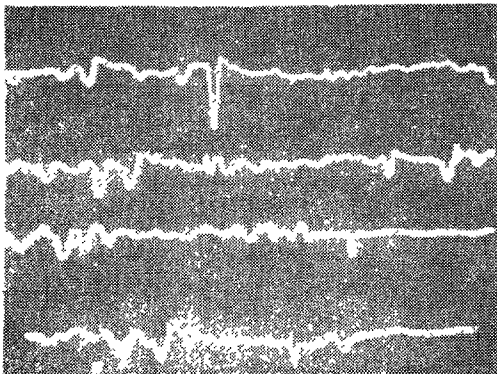


Fig. 3. Electromyography of tongue muscles reveals the denervation potentials and fibrillations.

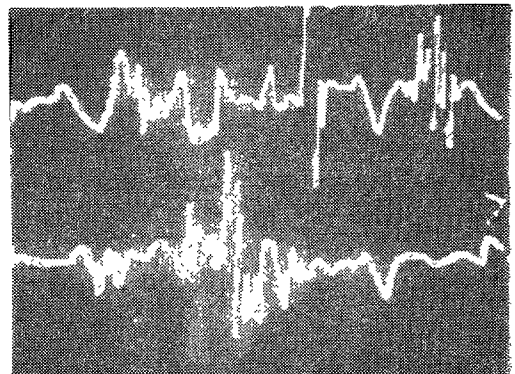


Fig. 4. Electromyography of the right sternocleidomastoid muscle reveals the polyphasic potentials.

Discussion

In 1849, Duchenne⁷⁾ described "muscular atrophy with fatty transformation" and a year later Aran²⁾, using Duchenne material, elaborated the description and named the condition progressive atrophy. In 1868 Charcot delivered a lecture at the Salpêtrière on the association of progressive muscular atrophy and sclerosis of the lateral columns, applying to this association the term ALS so that for a long time it was called Charcot's disease¹⁶⁾.

The causes of ALS remain unknown. But there are possible etiologies to be considered. In 1955, Ask-Upmark³⁾ reported motor neuron disease which developed in 5 patients after gastric resection and suggested that a metabolic imbalance might be etiologically related to ALS. Cumings⁶⁾ described abnormal pyruvated metabolism in 15 of 36 ALS patients and abnormalities in glucose utilization have been reported in other studies¹²⁾²⁰⁾. But there is no obvious explanation for the abnormality in pancreatic endocrine gland function which is suggested by the latter reports. Current theories postulate that the disease may be due to a slow virus infection of anterior horn cells and motor neurons, or less likely due to autoimmune mechanism whereby antibodies destroy anterior horn cells. The pathogenesis may be a combination since antibodies to anterior horn cells may result from the slow virus infection or from some other circulating toxin that destroys anterior horn cells. Several laboratories have shown that blood from patient with motor neuron disease destroys cultures of anterior horn cells and that excessive antibodies are present in many patients with motor neuron disease⁴⁾¹⁹⁾. The report of numerous familiar cases of ALS from the Chamorro population in the Marianas island has stimulated

great interest in a possibly genetic factor in the causation of this disease. But there is evidence that it may occur in non-Chamorro people who have lived on the island for many years. Therefore it is questionable that this form of ALS is hereditary⁸⁾⁹⁾.

ALS rarely occurs before the age of 35 years, with maximal incidence in the fourth and fifth decades. It afflicts man 2 to 3 times as often as it does women. Most authors conclude that inheritance does not play a significant role in the disease. However, there are reports of a number of families in which the disease has occurred in one or more members of several generations. There is an especially high occurrence in the Chamorro people of the island of Guam and Rota, which is possibly related to a hereditary factor¹⁴⁾¹⁶⁾¹⁷⁾. The familiar form is inherited as an autosomal recessive trait, and these cases often show atypical features such as paralysis of bladder and rarely impairment vibration sense in low extremities associated with otherwise typical signs and symptoms of motorneuron degeneration¹⁰⁾.

The pathology is essentially a degeneration of motor cells in the spinal cord, brain stem and, to a less extent, in the cerebral cortex, together with secondary degeneration of the fiber tracts in the lateral and ventral portion of the spinal cord. In appearance both the brain and spinal cord are essentially normal except that there may be atrophy of anterior roots. Microscopically, there is loss of motor neurons in layers 3 and 5 in the frontal lobe¹⁰⁾. Section of the brain stem shows degeneration in the corticospinal tracts and neuronal loss in motor cranial nerve nuclei. In the spinal cord the direct and indirect corticospinal tracts are degenerated with a striking loss of motor neurons in the anterior horns. The anterior nerve roots contain fewer motor fibers, while the

atrophic muscles is characteristic, with loss of muscle fibers in fascicle or in the distribution of motor units. There is usually no evidence of an inflammatory reaction, except the presence of a few phagocytes surrounding recently degenerated muscle fibers^{10,18}.

ALS may be classified into convenient subgroups according to site of involvement of central nervous system^{16,18}. If the degeneration is restricted to the motor cells in the cerebral cortex and the descending pathways from the cells to the motor nuclei in the spinal cord, the syndrome of primary lateral sclerosis would result^{16,18,21}. This syndrome consists of a spastic weakness of the muscles of the trunk and extremities with associated hyperactive deep reflexes, the Hoffmann reflex, the Babinski reflex and absent abdominal skin reflexes. In addition, if the fibers to the bulbar nuclei are affected, the syndrome of pseudobulbar palsy will be presented^{10,16,18,21}. Hence it is characterized by an exaggerated jaw jerk, an active sucking reflex, poor voluntary elevation of the soft palate, as on phonation, but good elevation in gag reflex. On the other hand limitation of the pathological changes to the motor nuclei in the brain stem produces the syndrome of progressive bulbar palsy. It is featured by wasting on both voluntary and reflex innervation, with poor palatal elevation in the gag reflex as well as in phonation, so that the voice is both nasal and hoarse as well as dysarthria, while dysphagia and drooling come early, followed by the danger of aspiration, nasal reflux of fluids and choking. Finally the tongue becomes atrophic and fasciculations appear, and the same is true of the face and muscles of mastication. In these cases the disease runs a rapid course and the patient rarely survives more than 18 months from the onset of symptoms^{10,16,18}. In an appreciable percentage (25 per cent) of the cases of ALS,

the initial symptoms are confined to the muscles innervated by the medulla, but in the majority of these cases, pseudobulbar symptoms or atrophy of the trunk and extremity develops with the course of one or two years. Degeneration restricted to the ventral horn cells of the spinal cord produces the syndrome of progressive spinal muscular atrophy¹⁸. In approximately thirds of the patients with ALS, the initial symptoms of the disease is weakness and wasting of the extremities^{16,23}.

Therefore, from the nature and distribution of the pathological change it is obvious syndrome or combinations of syndromes are possible.

Pains and paresthesias in the extremities occur in approximately one half of the cases. These pains can probably be explained as due to excessive strain on weakened muscles¹⁸. Urinary frequency, urgency, difficulty in initiating the stream or incontinence occurs in approximately 15 to 20 per cent of patients. These symptoms usually develop late in the course of the disease. But in familiar forms, there is no bladder involvement of sensory loss¹⁰.

Mental symptoms are not unusual. In the majority of the cases the mental symptoms are in the nature of explosive, uncontrollable outbursts of laughing, crying or an admixture of both. The affective outbursts are characteristic as a symptom of pseudobulbar palsy^{10,18}.

The disease progressed to terminal stage, secretions accumulated in the pharynx that can neither be swallowed nor expectorated. Death usually occurs from respiratory insufficiency and aspiration pneumonia.

With experience, it is possible to predict the period of survival in most cases. Patient with signs of progressive muscular atrophy with no spasticity have the best prognosis with survival exceeding ten years in some cases. But

one notes that after the onset of spinal spastic changes, patients live on the average 36.2 months: after spinal atrophic, nearly as long 33.0 months: after bulbar spastic only 24.6 months, and after bulbar atrophic involvement 17.3 months¹¹⁾¹⁶⁾²³⁾.

Diagnosis is usually confirmed by biopsy of involved muscles which shows the characteristic pattern of denervation atrophy with fascicles of in muscle fibers adjacent and subadjacent to atrophic groups of fibers corresponding to the pattern previously innervated by dividing axons. A slight increase in protein content in the cerebrospinal fluid, with values between 45 and 95 mg. per 100 cc. is found in one third of the cases. There is a decrease in the urinary output of creatinine and a slight increase in the output of creatine. EMG and measurement of nerve conduction velocity is usually normal but EMG usually shows widespread denervation patterns with fibrillations. Giant motor unit potentials on voluntary movement are a feature of anterior horn cell disease¹⁰⁾¹⁸⁾²¹⁾.

There is no treatment which will favorably influence the occurrence of the disease. Difficulties in chewing and dysphagia are usually minimized by a semisolid or liquid diet. Gastrostomy is indicated in patients with malnutrition due to bulbar paralysis. When respiratory insufficiency is such that assisted respiration is necessary, tracheostomy should be performed. Pain is not a problem in ALS, so that the use of narcotics is not indicated. However, the wide use of sedation for anxiety or depression may do much alleviate suffering in the terminal stage of this disease.

Summary

A case of syndrome of progressive bulbar palsy was reported and the clinical and EMG features were described.

—References—

- 1) Aran FA: Recherches sur une maladie non encore décrite du système musculaire (Atrophie musculaire progressive), Arch Gén Méd(4 series) 24 : 5—35, Sept; 172—214, Oct. 1850.
- 2) Arnold A, Edgren DC and Palludino US: Amyotrophic Lateral Sclerosis: 50 Cases Observed on Guam, J Nerv Ment Dis 117 : 135—139, 1953.
- 3) Ask-Upmark E: Amyotrophic lateral sclerosis in five persons after gastric resection. Gastroenterology 15 : 257, 1950.
- 4) Bornstein, MB: A tissue culture approach to demyelinating disorders. National Cancer Society Monograph No. 11. Symposium on Organ Culture, 197—214, 1962.
- 5) Charcot JM and Joffroy A: Deux Cas d'atrophie musculaire progressive avec lésions de la substance grise et des faisceaux antérolatéraux de la moelle épinière, Arch Physiol norm Path 2 : 354 (May); 629 (Sept); 744 (Nov), 1869.
- 6) Cumings JN: Biochemical aspects. Discussion on motor neuron disease. Proc. roy. Soc. Med 55 : 1023, 1962.
- 7) Duchenne(de Boulogne) and Guillaume BA: De l'Atrophie musculaire avec transformation graisseuse. De l'électricité localisée, Paris, Baillière, 622—624, 1855.
- 8) Elizan TS, Chen KM, Mathai KV, Dunn D and Kurland LT: Amyotrophic lateral sclerosis and Parkinsonism-dementia complex; a study in non-Chamorros of the Mariana and Caroline Island, Arch. Neurol., 14 : 347—355, 1966.
- 9) Elizen TS, Hirano A, Abrams BM, Need RL, Nuis CV, and Kurland LT: Amyotrophic lateral sclerosis and Parkinsonism-dementia complex of Guam; neurological reevaluation, Arch. Neurol., 14 : 356—368, 1966.
- 10) Gilroy J, Meyer JS: Medical Neurology. Macmillan Publishing Co., Inc. New York, Collier-Macmillan Canada, Ltd. Toronto, Bailliere Tindall. London. 200—204, 1975.
- 11) Greenfield JG: Amyotrophic Lateral Sclerosis, in Neuropathology, Edward Arnold, 545, 1958.
- 12) Ionasescu V and Luca N: Studies on carbohy-

- drate metabolism in Amyotrophic lateral sclerosis and hereditary spinal muscular atrophy. *Acta Neurol Scand* 40 : 47, 1964.
- 13) Koerner DR: Amyotrophic Lateral Sclerosis on Guam: A Clinical Study and Review of the Literature, *Ann Intern Med* 37 : 1204—1220, 1952.
 - 14) Kurland LT and Mulder DW: Epidemiologic Investigation of Amyotrophic Lateral Sclerosis: I. Preliminary Report on Geographic Distribution, With Special Reference to the Mariana Island, Including Clinical and Pathologic Observations, *Neurol* 4 : 355—378 (May); 438—448 (June) 1954.
 - 15) Kurland LT and Mulder DW: Epidemiologic Investigation of Amyotrophic Lateral Sclerosis: II. Familial Aggregations Indicative of Dominant Inheritance, *Neurol* 5 : 182—196 (March); 249—269 (April) 1955.
 - 16) Mackay RP: Course and Prognosis in Amyotrophic Lateral Sclerosis, *Arch Neurol*, 8, 117, 1963.
 - 17) Malamud N, Hirano A, Kurland LT: Pathoanatomic Changes in Amyotrophic Lateral Sclerosis on Guam: Special Reference to the Occurrence of Neurofibrillary Changes, *Arch. Neurol* 5 : 401—415, (Oct.) 1961.
 - 18) Merritt HH: *A Textbook of Neurology*. Lea & Febiger, Philadelphia. Igaku Shoin Ltd., Tokyo, Japan. 493—500, 1973.
 - 19) Oldstone MBA, Wilson CB, Norris FH, Jr., and Nelson E: Immunoglobulin deposits in amyotrophic lateral sclerosis. Problem of the 98th Annual Meeting, American Neurological Association, 1973.
 - 20) Steinke J and Tyler RH: The association of amyotrophic lateral sclerosis (motor neuron disease) and carbohydrate intolerance, a clinical study. *Metabolism* 13 : 1376, 1964.
 - 21) Walton JN: *Brain's Disease of the Nervous System*. 8th, 682—694.
 - 22) Welch KMA and Goldberg DM: Serum creatine phosphokinase in motor neuron disease. *Neurol.* 22 : 697—701, 1972.
 - 23) Wilson SAK: *Amyotrophic Lateral Sclerosis: Course and Prognosis*, in *Neurology*, London, Edward Arnold and Co., 2 : 1031, 1940.
 - 24) Wolfgram F and Myers L: Toxicity of serum from patients with amyotrophic lateral sclerosis for anterior horn cells in vitro, *Trans. Am. Neurol. Assoc.*, 97 . 19—21, 1972.
-