

Ectopic Pregnancy Implanted on Uterine Myoma

Min Kyoung Kim, Hyun Soo Park, Myung Hwa Lee, Sung Hee Kim, Jung Hwan Shin

Department of Obstetrics and Gynecology, Eulji General Hospital, University of Eulji College of Medicine, Seoul, Korea

Ectopic pregnancy is an implantation of the fertilized ovum outside the uterine cavity. Most of ectopic pregnancies are located within the fallopian tube. We describe a rare case of 34-year-old woman complaining of lower abdominal pain and positive urinary pregnancy test. Pelvic ultrasound exam suggested tubal pregnancy with hemoperitoneum. However, pelviscopy revealed the bleeding point was subserosal myoma located just next to the right ovary. Uterus and both fallopian tubes were grossly free. Laparoscopic myomectomy with ectopic mass excision was performed and we observed the serial decrease of β -hCG level. Patient was well recovered and postoperative finding was not remarkable. Hereby, we report a rare case of ectopic pregnancy on uterine myoma with subserosal type with a brief review of literatures. (**Ewha Med J 2015;38(3):126-128**)

Received April 13, 2015

Accepted July 2, 2015

Corresponding author

Jung Hwan Shin
Department of Obstetrics and Gynecology,
Eulji General Hospital, University of Eulji
College of Medicine, 68 Hangeulbiseong-ro,
Nowon-gu, Seoul 01830, Korea
Tel: 82-2-970-8245, Fax: 82-2-970-8429
E-mail: sjh3102@eulji.ac.kr

Key Words

Ectopic pregnancy; Myoma; Ovarian neoplasm; Myomectomy; Laparoscopy

Introduction

Ectopic pregnancy is a very common diagnosis (2% of pregnancies) and implantation location varies. About 97% of ectopic pregnancies are implanted within the fallopian tube, and ectopic implantation can occur in other pelvic and abdominal locations [1]. Although very rarely reported, non-tubal ectopic pregnancies might lead to significant diagnostic challenge and morbidity. We report the first case of subserosal myoma ectopic pregnancy, confirmed by laparoscopy and biopsy result.

Case

The patient was a 34-year-old, gravida 2 para 1 woman. Her last childbirth was 4 years ago. At admission, the patient was complaining moderate lower abdominal pain. Her last menstrual period was 7 weeks ago and urinary pregnancy test was positive. Her initial blood pressure was 110/80 mmHg, pulse was 72 beats per minute and she was afebrile. The patient's abdomen was soft with lower abdominal tenderness. Trans-vaginal sonography re-

vealed an empty uterine endometrium with 2.35×2.28 cm sized hypoechoic cystic shadow adjacent to the right adnexa (Fig. 1). The anterior cul-de-sac fluid collection was 4.03 cm suggesting

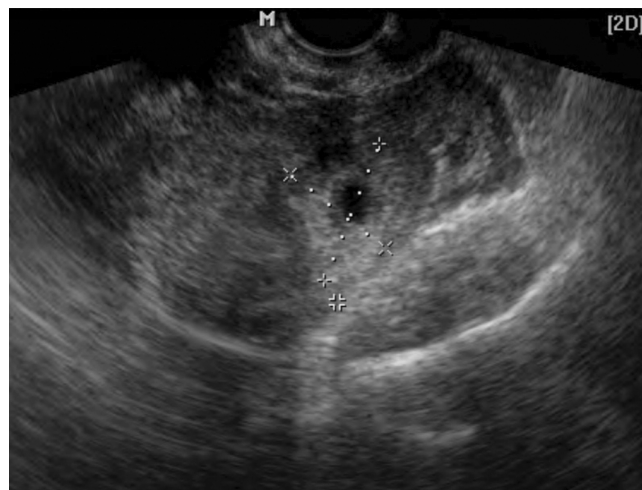


Fig. 1. Vaginal sonography. It reveals empty endometrium in uterus with 1.05 cm sized G-sac like shadow around the right ovary is observed.

hemoperitoneum. Measure of β -hCG was 11,941.1 at presentation.

Initial vital sign was stable, but the patient complained of aggravating pain with notable abdominal distension. Emergency laparoscopy was arranged directly. On operation field, about 500 mL blood collection was seen in pelvic cavity. A bleeding point was noted on the subserosal uterine myoma (2×2 cm) between the right upper body of uterus and right ovary (Fig. 2). The whole mass including myoma was ligated with an endo-loop and cut with laparoscopic scissors. The specimen was put in endo-pouch and taken out completely. Dilatation and curettage was done for assuring ectopic pregnancy. Pathologic findings confirmed ectopic pregnancy on uterine myoma; several fragments of myomatous nodule, aggregating about 3.0×2.2×1.8 cm and a separate villous like tissue with blood clot, aggregating about 2.5 mL blocked in myomatous nodule and villous like tissue. Tissues from endometrial curettage showed late secretory phase with predecidual change. The patient was followed up with serial β -hCG measures and trans-vaginal ultrasonography. The level of β -hCG was 2,128.4 IU/mL on the second day and 54.5 IU/mL on the 12th day after the operation.

Discussion

Ectopic pregnancy constitutes 2% of total pregnancy. They are commonly seen in women with history of tubal ligation or pelvic inflammatory disease (PID) and in women with intra-

uterine device (IUD) for contraception. Ectopic pregnancy is also common in women on medication for infertility. Studies have shown that ovulation induction drug, especially with clomiphene citrate, was an independent risk factor of ectopic pregnancy. Techniques applied in the fallopian tubes, such as zygote and gamete intrafallopian transfer (ZIFT and GIFT), also increased the rate of ectopic pregnancies [2].

Ectopic pregnancy is responsible for the main cause of maternal mortality. We should consider ectopic pregnancy in all women with positive pregnancy test accompanied by abdominal pain or vaginal bleeding. Also, we have to take into account of the possibility of ectopic pregnancy in all case of no intrauterine gestational sac in ultrasonography despite the level of β -hCG is already above the discriminatory zone. We cannot be too careful doubting ectopic pregnancy.

Ninety-seven percent of ectopic pregnancies are located in fallopian tube. Therefore, we may find out ectopic product with ultrasound evaluation of adnexa. But, 2% are ovarian, and the remainder are cervical or abdominal. Also, there are increasing numbers of pregnancies reported within the scar left by caesarean sections [3]. As we experienced, uterine myoma can't be an exception of ectopic implantation site.

A mechanism that probably can explain ectopic pregnancy on uterine myoma of subserosal type is an invasion of the aborted G-sac expelled out from the tubal pregnancy. Another possible mechanism could be a secondary implantation of the abdominal ectopic pregnancy to the pedunculated subserosal myoma. In

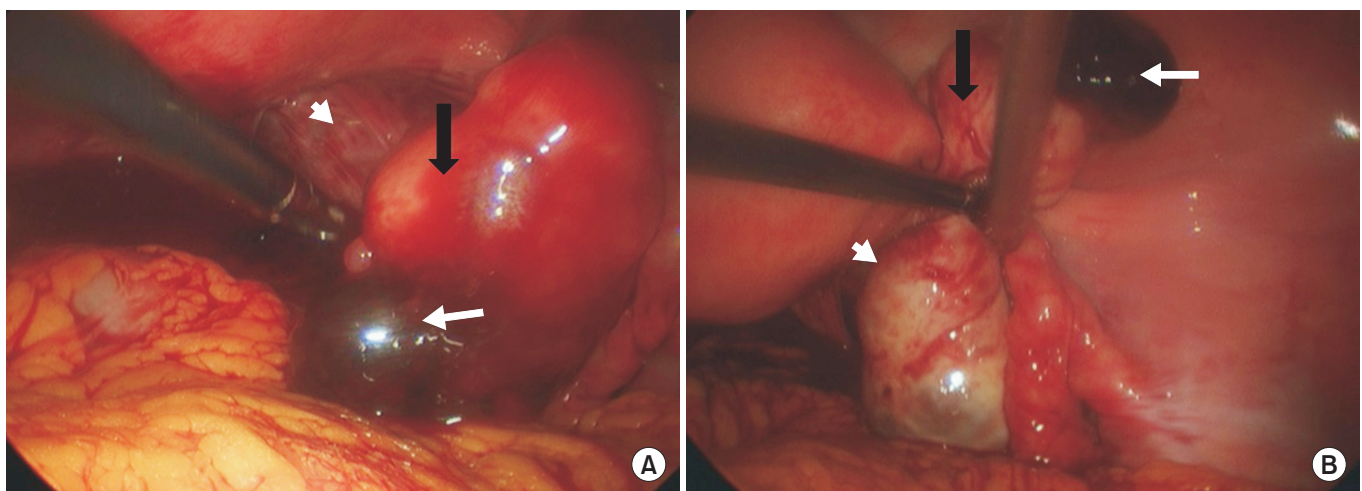


Fig. 2. Laparoscopic findings. It shows ectopic pregnancy on subserosal uterine myoma (A), normal ovary and tube (B) (black arrow, myoma; white arrow, ruptured G-sac; shot white arrow, ovary).

these possible mechanisms, the first step will be a formation of new microscopic tract of myometrium to the subserosal myoma after trauma from previous uterine surgeries such as curettage, cesarean delivery, myomectomy and hysteroscopy [4-6]. Then aborted ectopic G-sac implantation may occur in uterine myoma. In this case, primary ectopic pregnancy site might be the salpinx seeing that final ruptured point is the subserosal myoma adjacent to the fallopian tube. Although abdominal ectopic pregnancy could happen anywhere in abdominal cavity, uterine myoma is usually consisted with smooth muscle cells with a few superficial vessel distributed on its capsule is not so hard to implant on.

Because of the rarity of subserosal myoma as an implantation site of ectopic pregnancy, it is not easy to suspect on pelvic sonography at first. In addition to that, subserosal myoma extended laterally from the uterus and may be confused with adnexal or fallopian masses [7]. Mapping of the vascular supply to these myoma can help to distinguish them from adnexal or retroperitoneal tumors including ectopic pregnancies [8,9].

There are no universal treatment guidelines nor preferred treatment consensus for ectopic pregnancy implanted on the subserosal myoma. However, like in tubal pregnancy, if ruptured, surgical treatment is the treatment of choice. The different thing is in this case, salpinx can be preserved safely because myomectomy is enough to control the bleeding source. Because ectopic pregnancy on subserosal myoma is uncommon entity, a high index of suspicion and the use of trans-vaginal Doppler sonography can help early diagnosis. Because, doppler gives information about the location and degree of blood flow in and around pelvic lesions without the need to inject contrast. So, doppler ultrasound imaging can evaluate the mapping and den-

sity of blood flow and even provide a quantitative measure of the amount of blood flow in the implantation site [10,11]. We should keep in mind that patient's subserosal myoma could be a site of ectopic pregnancy.

References

1. Fylstra DL. Ectopic pregnancy not within the (distal) fallopian tube: etiology, diagnosis, and treatment. *Am J Obstet Gynecol* 2012;206:289-299.
2. Strandell A, Thorburn J, Hamberger L. Risk factors for ectopic pregnancy in assisted reproduction. *Fertil Steril* 1999;71:282-286.
3. Condous G, Okaro E, Alkatib M, Khalid A, Rao S, Bourne T. OC198: should an ectopic pregnancy always be diagnosed using transvaginal ultrasonography in the first trimester prior to surgery? *Ultrasound Obstet Gynecol* 2003;22(S1):53.
4. Fait G, Goyert G, Sundareson A, Pickens A Jr. Intramural pregnancy with fetal survival: case history and discussion of etiologic factors. *Obstet Gynecol* 1987;70(3 Pt 2):472-474.
5. McGowan L. Intramural pregnancy. *JAMA* 1965;192:637-638.
6. Miller DA, Chollet JA, Goodwin TM. Clinical risk factors for placenta previa-placenta accreta. *Am J Obstet Gynecol* 1997;177:210-214.
7. Katz VL. *Comprehensive gynecology*. 5th ed. Philadelphia: Mosby Elsevier; 2007.
8. Woodward PJ, Gilfeather M. Magnetic resonance imaging of the female pelvis. *Semin Ultrasound CT MR* 1998;19:90-103.
9. Ueda H, Togashi K, Konishi I, Kataoka ML, Koyama T, Fujiwara T, et al. Unusual appearances of uterine leiomyomas: MR imaging findings and their histopathologic backgrounds. *Radiographics* 1999;19 Spec No:S131-S145.
10. Taskin S, Taskin EA, Cengiz B. Cervical intramural ectopic pregnancy. *Fertil Steril* 2009;92:395.e5-395.e7.
11. Benacerraf BR, Abuhamad AZ, Bromley B, Goldstein SR, Grozsmann Y, Shipp TD, et al. Consider ultrasound first for imaging the female pelvis. *Am J Obstet Gynecol* 2015;212:450-455.