

Intractable Atrial Flutter Successfully Treated with Flecainide and Propranolol in a Premature Infant

Min Ju Lee, Se Hwan Ahn, Jong Han Kim, Su Yeong Kim, Ji-Eun Ban¹

Department of Pediatrics, Hallym University Kangdong Sacred Heart Hospital, ¹Department of Pediatrics, Ewha Womans University School of Medicine, Seoul, Korea

Although Atrial flutter (AFL) in newborn infant with normal cardiac anatomy has benign clinical course, an intractable AFL is associated with an increased risk of development of heart failure and sudden death, and is still difficult to manage. It requires multiple external electrical cardioversions, and it shows a poor response to antiarrhythmic drug therapy. We report a case of a premature infant with an intractable AFL, which we successfully treated with oral flecainide and propranolol in spite of recurred AFL. A 1-month-old, 34-week gestation, premature baby presented with an irregular heart beat and irritability. An AFL with 2:1 atrioventricular conduction was documented. Because of the intractable AFL, repeated electrical cardioversion and amiodarone were continued for 14 days. However, amiodarone was discontinued in favour of flecainide and propranolol because of the recurrent AFL and newly developed transient hypothyroidism. During 1-year follow-up period, in which oral flecainide and propranolol were continued, no AFL was observed. (**Ewha Med J 2017;40(3):140-142**)

Received June 16, 2017

Revised July 7, 2017

Accepted July 10, 2017

Corresponding author

Ji-Eun Ban

Department of Pediatrics, Ewha Womans
University School of Medicine, 1071

Anyangcheon-ro, Yangcheon-gu, Seoul 07985,
Korea

Tel: 82-2-2650-2663, Fax: 82-2-2653-3718

E-mail: jeban@naver.com

Key Words

Atrial flutter; Premature infant; Flecainide

Introduction

Neonatal atrial flutter (AFL) has a usually benign clinical course in patients with normal structural hearts. However, an AFL can be potentially lethal in cases of recurrent attack and can result in complications, such as congestive heart failure. Moreover, an intractable AFL requires multiple external electrical cardioversions, and it demonstrates a poor response to antiarrhythmic drug therapy [1-3]. Here, we report a case of intractable AFL which was successfully controlled with flecainide and propranolol therapy in a premature infant.

Case

A 1-month-old premature infant was referred to Kangdong

Sacred Heart Hospital (Seoul) because of an irregular heart beat with irritability. He was born at 34 weeks' gestation with a birth weight of 2.07 kg. There was history of maternal gestational diabetes. At birth, the infant had a history of a small perimembranous ventricular septal defect. A baseline surface electrocardiogram revealed a frequent atrial premature complex (APC) with intermittent non-conduction and aberrant conduction (Fig. 1). A follow-up two-dimensional echocardiogram showed a nearly closed ventricular septal defect with normal ventricular function and a normal upper left ventricular end-diastolic dimension. Mild cardiomegaly with cardiothoracic ratio, 0.58 was observed on a chest roentgenography. After admission at a neonatal intensive care unit, AFL with 2:1 atrioventricular conduction with a ventricular rate of 198 beats/min was documented based on electrocardiogram monitoring (Fig.

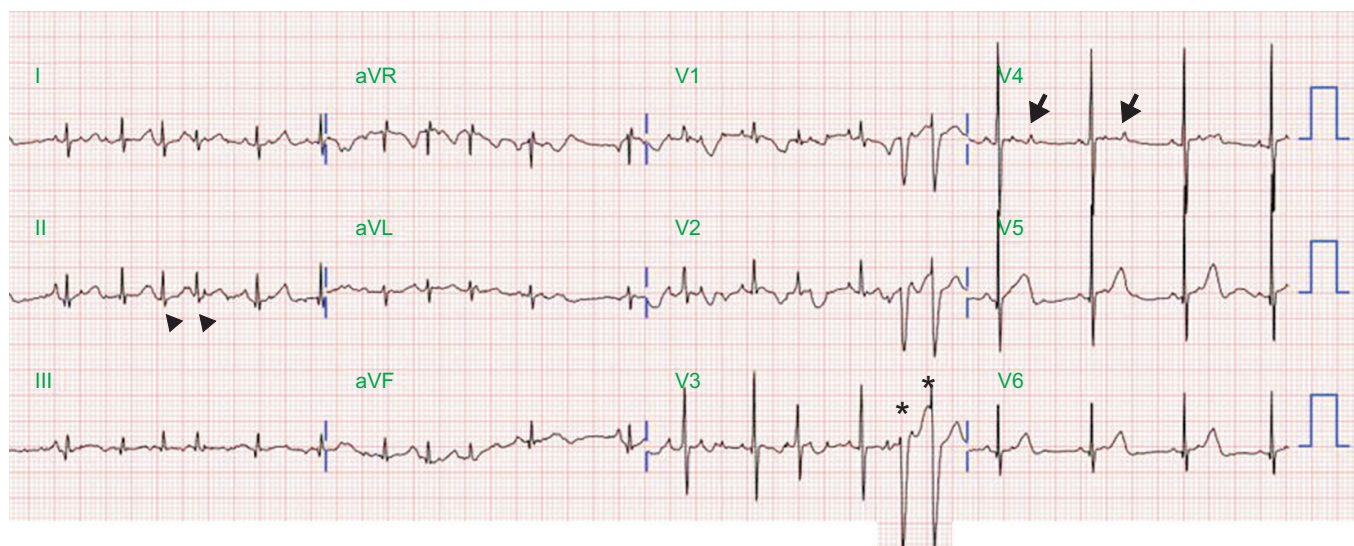


Fig. 1. A baseline 12-lead surface electrocardiogram. Premature atrial complexes (arrowhead) with non-conduction (arrow) and aberrant conduction (asterisk) are shown. aVR, augmented vector right; aVL, augmented vector left; aVF, augmented vector foot.

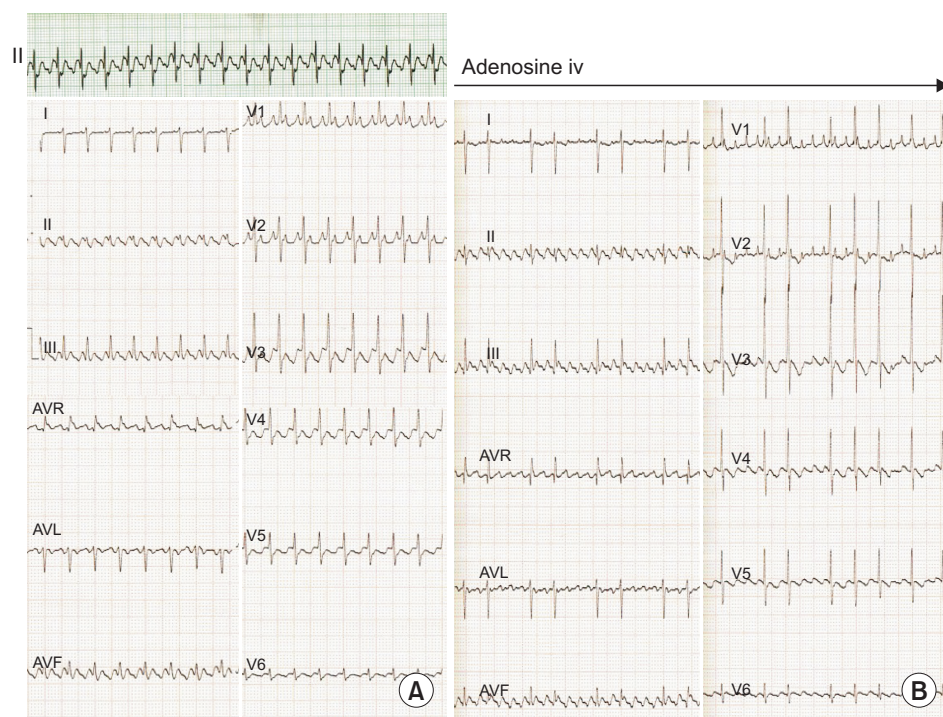


Fig. 2. Atrial flutter on an electrocardiogram. (A) A rhythm strip electrocardiogram showed narrow QRS tachycardia, with a ventricular rate of 198 beats/min. Atrial flutter with 2:1 atrioventricular conduction was documented on 12-lead electrocardiogram. (B) After the adenosine injection, a 12-lead surface electrocardiogram showed atrial flutter, with variable atrioventricular conduction and an atrial rate of 300 beats/min. AVR, augmented vector right; AVL, augmented vector left; AVF, augmented vector foot.

2A). Adenosine was administered, and an AFL was observed with variable atrioventricular conduction at an atrial rate of 300 beats/min (Fig. 2B). Although electrical cardioversion (1 J/kg) terminated the AFL, the intravenous loading of amiodarone was infused, and then a maintenance dose of oral amiodarone was administered because of the intractable AFL. While remain

normal sinus rhythm, frequent APCs were seen. On day 14, the AFL with 2:1 atrioventricular conduction recurred. Synchronized electrical cardioversion was performed, and sinus rhythm was restored. A non-conducted APC was frequently observed on the electrocardiogram telemetric monitoring. Moreover, the neonate developed transient hypothyroidism. Therefore, amiodarone was

discontinued on day 17, and oral flecainide and propranolol were simultaneously administered. After titration of propranolol over 7 days and flecainide over 8 days, we reached to the therapeutic range of flecainide (5 mg/kg/day) and propranolol (3 mg/kg/day). And no more APCs were observed over 10 days. Following an increased dosage of flecainide and propranolol, there was no AFL recurrence. However, the infant suffered from respiratory syncytial viral infection. Because of the underlying laryngomalacia with a co-pulmonary infection, he required ventilator support. Despite prolonged hospital stays under respiratory care, the infant did not demonstrate AFL or an APC. The neonate was discharged with oral flecainide and propranolol therapy on day 34. During 1 year of chronic oral antiarrhythmic therapy, there was no recurrence of AFL. In addition, no proarrhythmic side effects were documented. And he has been free of AFL during the 10-month follow-up period without antiarrhythmic medication.

Discussion

In this report, we presented a case of a premature infant with an intractable AFL, which we initially treated with repeated electrical cardioversion and intravenous amiodarone, but this treatment did not demonstrate strong control of the condition. Under oral amiodarone maintenance therapy, a recurrent AFL occurred, and transient hypothyroidism developed. After substituting the amiodarone with other combination therapy (i.e., flecainide and propranolol), the intractable AFL was suppressed. In this case, frequent APC probably as the trigger for the recurrence of the AFL. Baseline surface electrocardiography demonstrated frequent APCs with aberrant conduction or non-conduction prior to AFL occurrence. In addition, APCs were frequently seen whenever AFL was terminated. Finally, AFL was not recurred after controlled APCs with flecainide and propranolol. We assumed that atrial ectopy may lead to the initiation of reentrant mechanism of AFL.

Prior studies have shown that electrical cardioversion and intravenous use of antiarrhythmic drugs therapy, such as amioda-

rone, propafenone, and flecainide, are usually the most effective therapy for the acute termination of neonatal AFL [4,5]. Only a few case reports have investigated using antiarrhythmic drug therapy to treat intractable AFL in a premature baby [6,7]. Flecainide is a class IC antiarrhythmic drug that act primarily slows conduction by depressing the maximum rate of the rise of depolarization of the action potential with minimal prolongation of refractoriness. And propranolol is a non-selective beta blocker with atrioventricular node blocking. Perhaps the flecainide and propranolol helped suppress these. There is much good evidence that oral combination therapy with a class IC antiarrhythmic drug combined with a beta blocker is effective at suppressing intractable AFL in a premature infant. To our knowledge, in the literature, there are no case reports in which a premature infant was successfully treated with oral flecainide and propranolol without any proarrhythmic side effects. Therefore, these combination therapies may be considered to an effective therapy in this special clinical setting.

References

1. Dunnigan A, Benson W Jr, Benditt DG. *Atrial flutter in infancy: diagnosis, clinical features, and treatment. Pediatrics* 1985;75:725-729.
2. Casey FA, McCrindle BW, Hamilton RM, Gow RM. *Neonatal atrial flutter: significant early morbidity and excellent long-term prognosis. Am Heart J* 1997;133:302-306.
3. Texter KM, Kertesz NJ, Friedman RA, Fenrich AL Jr. *Atrial flutter in infants. J Am Coll Cardiol* 2006;48:1040-1046.
4. Suzumura H, Nitta A, Ono M, Arisaka O. *Neonatal intractable atrial flutter successfully treated with intravenous flecainide. Pediatr Cardiol* 2004;25:154-156.
5. Gulletta S, Rovelli R, Fiori R, Bella PD. *Multiple external electrical cardioversions for refractory neonatal atrial flutter. Pediatr Cardiol* 2012;33:354-356.
6. Knirsch W, Kretschmar O, Vogel M, Uhlemann F, Bauersfeld U. *Successful treatment of atrial flutter with amiodarone in a premature neonate: case report and literature review. Adv Neonatal Care* 2007;7:113-121.
7. Obidi E, Toubas P, Sharma J. *Atrial flutter in a premature infant with a structurally normal heart. J Matern Fetal Neonatal Med* 2006;19:113-114.