

## Preventing Anastomotic Leakage, a Devastating Complication of Colorectal Surgery

Hyun Gu Lee 

Department of Surgery, Kyung Hee University Hospital at Gangdong, Kyung Hee University School of Medicine, Seoul, Korea

**Received** Sep 3, 2023  
**Revised** Oct 11, 2023  
**Accepted** Oct 12, 2023

### Corresponding author

Hyun Gu Lee  
Department of Surgery, Kyung Hee  
University Hospital at Gangdong, Kyung  
Hee University School of Medicine,  
892 Dongnam-ro, Gangdong-gu, Seoul  
05278, Korea  
Tel: 82-2-440-8196  
Fax: 82-2-440-6295  
E-mail: 02230006@khnmc.or.kr

### Key Words

Anastomotic leakage; Colorectal surgery;  
Indocyanine green

Anastomotic leakage (AL) after colorectal surgery is a significant concern, as it can lead to adverse functional and oncologic outcomes. Numerous studies have been conducted with the aim of identifying risk factors for AL and developing strategies to prevent its occurrence, thereby reducing the severe morbidity associated with AL. The intraoperative method for reducing AL includes a mechanical assessment of AL, an assessment of bowel perfusion, drain placement, and the creation of diverting stomas. The anastomosis technique is also associated with AL, and the appropriate selection and accurate application of anastomotic methods are crucial for preventing AL. Indocyanine green fluorescence imaging has recently gained popularity as a method for assessing bowel perfusion. While it is useful for detecting bowel perfusion, standardized protocols and measurement methods need to be established to ensure its reliability and effectiveness in clinical practice. The use of intraoperative drains to reduce AL has produced inconsistent results, and the routine adoption of this practice is not currently recommended. Diverting stomas can be used to help reduce the morbidity associated with AL. However, it is important to carefully consider the complications that can arise directly from the stoma itself. It should be noted that while a stoma can reduce AL, it cannot completely prevent it. This descriptive review examines various intraoperative methods aimed at reducing AL, discussing their effectiveness in reducing AL.

## Introduction

Despite advancements in treatment and the establishment of a comprehensive nationwide screening program, the mortality rate from colorectal cancer (CRC) continues to be a significant concern in Korea [1]. Furthermore, the expenses related to the treatment of CRC and the management of its associated side effects pose a considerable societal burden.

Currently, the primary treatments for CRC include surgical procedures, radiotherapy, and chemotherapy [2,3]. Encouraging outcomes are being seen in a specific subgroup of patients through targeted therapy and immunotherapy [4,5]. Surgery is typically the first line of treatment for CRC. Significant advancements in the comprehensive management of CRC have been made due to improvements in surgical resection and anastomosis techniques, as well as the use of innovative instruments.

Nonetheless, surgical complications are an inherent part of the procedure, and among these, anastomotic leakage (AL) stands out as a particularly concerning complication following surgery for CRC. Studies have shown that AL can negatively impact functional outcomes and may

potentially contribute to cancer recurrence [6–8].

Over the past few decades, there has been a notable expansion in the use of minimally invasive procedures, including laparoscopic surgery, robotic approaches, and trans-anal mesorectal excision. These advancements have increased the likelihood of sphincter preservation [9–12]. Importantly, as the use of sphincter-preserving techniques continues to rise, so does the population of patients potentially at risk for AL. Consequently, efforts to predict, prevent, and appropriately treat AL following rectal cancer surgery have become increasingly critical.

In this descriptive review, we aim to explore the risk factors associated with AL following rectal cancer surgery and provide an overview of recent surgical techniques applied during and after surgery for prevention, as well as insights into treatment approaches.

---

## Intraoperative Approach to Reduce Anastomotic Leakage

### 1. Anastomosis method and configuration

Hand-sewn and stapled anastomoses are still widely performed, with the choice between the two largely dependent on individual surgeons' preferences. This is due to the ongoing debate regarding which method is safer. The essential points for ensuring safe bowel anastomosis, whether hand-sewn or stapled, include meticulous technique, adequate blood supply, and the absence of tension [13]. The choice of anastomosis method and configuration is influenced by various factors, such as the surgical approach, intestinal tension, and the surgeon's level of experience.

There is no conclusive evidence supporting the superiority of any specific method of constructing colorectal anastomoses, including the side-to-side, end-to-side, side-to-end, or end-to-end techniques. At present, the double-staple technique is the most commonly employed method for colorectal anastomoses [14–16], especially given the widespread adoption of minimally invasive surgery. With regard to the double-staple technique, it has been suggested that the number of staple cartridges used for rectal division may be linked to AL, although the findings have not been consistently conclusive [17–19].

Some colorectal surgeons aim to minimize the number of cartridges used during rectal surgery by delicately trimming the rectum to allow for a single stapler firing to transect it. However, inserting a staple to transect the rectum can be particularly challenging in obese male patients with low, bulky tumors and narrow pelvises. It has been suggested that two cartridges be intentionally used for rectal transection, followed by the removal of the intersection of staple lines using a circular stapler. The use of a suprapubic port might be beneficial in reducing multiple stapler firings by facilitating vertical rectal division [20].

The "dog-ear" deformities created at both edges of the rectal stump after rectal division are considered a risk factor for AL in the double stapling technique. Some have demonstrated a technique that involves centrally invaginating the bilateral dog-ears using sutures to eliminate the dog-ears. Subsequently, both the staple line and the dog-ears are excised using a circular stapler [21,22]. In instances of proximal bowel dilation, to reduce the risk associated with anvil application, De Robles proposed a triple stapling technique [23]. This method involves using a linear stapler with an internal anvil to cut the proximal end, followed by creating an opening to remove the anvil spike prior to forming the anastomosis.

Intraoperative reinforcement of the anastomosis with sutures may be associated with a reduced occurrence of AL. However, the existing research evidence is somewhat constrained,

as many of the studies analyzed did not include patients with factors like neoadjuvant therapy or prophylactic stomas [24–28]. Recently, the use of intracorporeal circular reinforcing sutures has been introduced, utilizing barbed sutures for minimally invasive rectal surgery (Fig. 1). Although this technique could potentially be more easily implemented with a robotic approach, additional research is necessary to confirm its effectiveness in reducing AL.

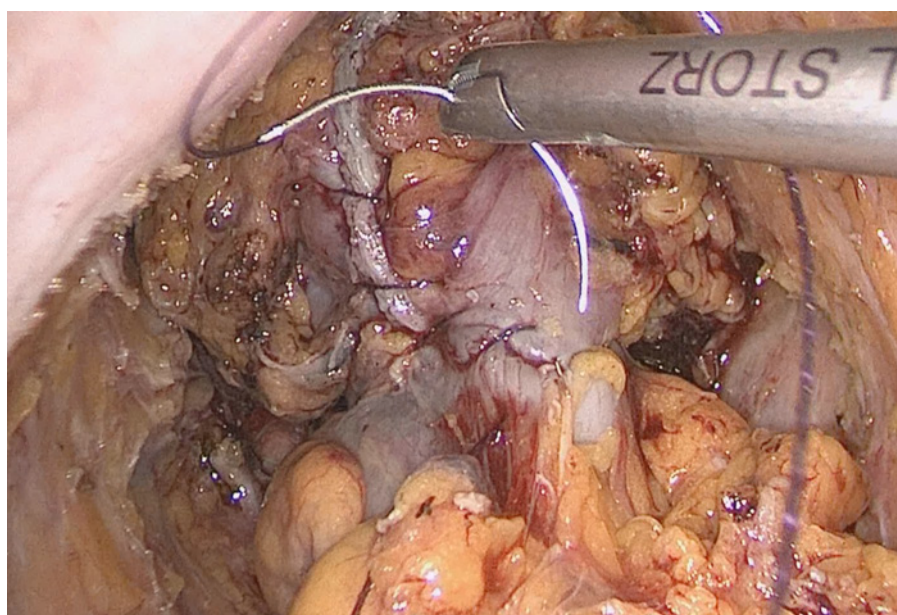
## 2. Intraoperative assessment of bowel blood perfusion

Maintaining optimal blood flow is crucial for ensuring a safe anastomosis. Traditionally, surgeons have evaluated bowel perfusion during an anastomosis procedure by observing the bowel's color or the presence of pulsatile flow at the cut surface of the bowel or marginal vessel. However, these methods can be subjective and occasionally insufficient.

Ryu et al. [29] attempted to determine the perfusion status by grading the bleeding of marginal vessels during left colon cancer surgery. They proposed a visual grading system that categorizes the bleeding from the marginal vessel into four groups. Despite not observing a difference in the AL rate among the groups due to the absence of AL occurrences during the study period, they discovered a correlation between age and the perfusion status of the proximal bowel, as determined by the visual grading system.

The use of indocyanine green (ICG) to assess bowel perfusion during surgery has recently garnered increasing interest [30]. Fluorescence imaging with ICG facilitates the clear delineation of vascular and avascular segments. This assists in establishing a well-perfused anastomosis, which may help prevent AL. There is a growing body of evidence supporting its effectiveness in reducing AL following colorectal surgery [30–33].

The PILLAR study demonstrated a reduced incidence of AL when intraoperative angiography was utilized. Specifically, the study reported a 1.2% incidence rate for low-risk left-sided anastomoses, and a 1.9% rate for high-risk cases. High-risk cases were defined as those



**Fig. 1.** Intracorporeal circular reinforcing sutures around a colorectal anastomosis following robotic low anterior resection. A continuous suture was done, including the linear-cut surface of rectal transection and circular anastomosis with a barbed suture. Unpublished photos of Sung Soo Yang with permission.

involving anastomoses located less than 10 cm from the anal verge and/or in patients who had undergone pelvic radiation [32]. Shen et al. performed an analysis of four studies, which included a total of 1,177 patients. Their results indicated a combined OR of 0.27 (95% CI, 0.13–0.53) favoring intraoperative angiography ( $P < 0.001$ ) [33].

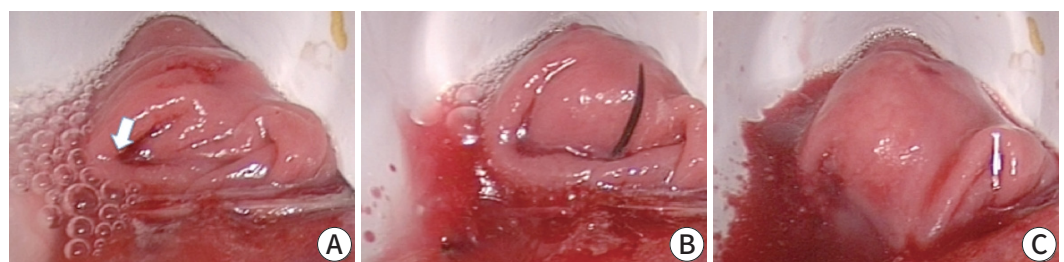However, it should be noted that ICG imaging, while useful, has the limitation of not being able to objectively quantify the degree of perfusion. As a result, there have been studies conducted with the aim of establishing a grading system for perfusion assessment. A study by Kim et al. [34] proposed a five-tier grading system for this purpose, considering both perfusion time and intensity. This study involved 657 patients who underwent curative robot-assisted sphincter-saving surgery for rectal cancer. The findings revealed that delayed perfusion ( $>60$  s) and low perfusion intensity (rated 1–2) were significantly more common in patients with anastomotic strictures and marginal artery defects, compared to those without these factors ( $P \leq 0.001$ ).

These findings suggest that integrating ICG fluorescence angiography into colorectal surgery could potentially be beneficial for preventing AL. However, it is essential to establish standardized protocols and develop objective evaluation methods for its practical implementation.

### 3. Intraoperative assessment of anastomotic integrity

Surgeons have employed various mechanical intraoperative techniques to evaluate the integrity of anastomoses to reduce AL in colorectal surgery. The air leak test has traditionally been used during surgery as a method to evaluate the integrity of anastomosis. This test involves insufflating the bowel at the anastomotic site to identify any defects in the anastomosis, allowing for immediate repair if necessary. While this test can effectively detect mechanical faults intraoperatively, it has limitations in identifying anastomotic leaks caused by poor perfusion and its use in low colorectal or coloanal anastomosis. A modified method to address the limitations of the conventional air leak test has been suggested [35]. Crafa et al. [35] proposed the direct observation of air leaks within the anastomosis using a circular anal dilator under pneumoperitoneum (Fig. 2). However, as they also utilized ICG imaging, it is difficult to conclude that the modified air leak test alone was effective in reducing AL.

Intraoperative endoscopy has been used to evaluate the integrity of anastomoses, enabling the identification of bleeding at the anastomotic level or disruption of the anastomosis during surgery [36]. Endoscopy may also manage anastomotic bleeding, as it can be employed in a postoperative setting [37]. A systematic review and meta-analysis of six studies revealed that intraoperative endoscopy was linked with a decrease in postoperative AL (from 6.9% to 3.5%; OR=0.37; 95% CI, 0.21–0.68;  $P=0.001$ ) and anastomotic bleeding (from 5.8% to 2.4%; OR=0.35; 95% CI, 0.15–0.82;  $P=0.02$ ) in left-sided colon resection [36]. However, the air leak test using



**Fig. 2.** Modified reverse air-leak test. (A) An air bubble is assessed within the rectum using circular anal dilator after filling the rectum with water. (B) A reinforcing suture is applied. (C) The absence of an air-leak is confirmed. Adapted from Crafa et al. [35] with CC-BY.

endoscopy requires endoscopic skills, additional materials, and is time-consuming. Furthermore, its effectiveness in preventing AL in colorectal surgery requires further scientific validation.

While there may be debates about the effectiveness of mechanical intraoperative methods in reducing AL, they can still be valuable for identifying immediate technical issues.

#### **4. Role of drainage in preventing or detecting anastomotic leakage**

A trans-anal drain can potentially alleviate endo-luminal pressure at the anastomotic site and facilitate drainage on the proximal side of the anastomosis. It may also offer protection against watery stool or gas, and theoretically decrease bacterial contamination in the area, thus potentially preventing AL following rectal surgery. However, the outcomes of various studies have been inconsistent, casting doubt on the effectiveness and validity of trans-anal drainage [38,39]. A meta-analysis involving 909 participants (401 with trans-anal tubes and 508 without) from four trials concluded that the use of a trans-anal tube is an effective and safe procedure that can reduce the incidence of AL [38]. The group with the trans-anal drain exhibited a significantly reduced risk of AL compared to the group without the drain (OR=0.30; 95% CI, 0.16–0.55; P=0.0001). Additionally, there were notable differences between the two groups in terms of the reoperation rate (OR=0.18; 95% CI, 0.07–0.44; P=0.0002) in this meta-analysis. However, more recent analyses have presented contradictory findings [39]. These included three randomized controlled trials (RCTs) and 16 observational studies (both prospective and retrospective), involving a total of 4,560 patients. Interestingly, the impact of the trans-anal drain varied depending on the type of study. In the RCTs, the use of a trans-anal drain was not significantly associated with differences in AL (OR=0.67; 95% CI, 0.42–1.05; P=0.08). However, it was linked to a significant reduction in reoperation (OR=0.11; 95% CI, 0.03–0.51, P=0.004) and an increased rate of anastomotic bleeding (OR=2.36; 95% CI, 1.11–5.01; P=0.03). In observational studies, the use of a trans-anal drain was associated with a significant reduction in both AL (OR=0.44; 95% CI, 0.30–0.64; P<0.0001) and reoperation (OR=0.47; 95% CI, 0.33–0.69; P<0.0001). The conclusion drawn from these studies suggests that trans-anal drainage tubes may not clearly demonstrate superiority in reducing AL. Therefore, the use of trans-anal drainage to prevent AL is not currently recommended with a high level of evidence. However, well-designed future studies are warranted to evaluate its potential role.

The practice of prophylactic intra-abdominal drainage during elective colorectal surgery was once thought to be beneficial for the early detection of AL. However, recent studies have reported that this prophylactic measure does not reduce the incidence of AL [40,41]. The GRECCAR 5 trial, which compared 236 patients in the intra-abdominal drain group to 233 patients without drainage undergoing rectal cancer surgery, found that the use of intra-abdominal drainage did not result in a decrease in the rates of pelvic sepsis, postoperative morbidity, reoperation, length of hospital stay, or the rate of stoma closure [40]. A meta-analysis of a systematic review of four RCTs, including the GRECCAR 5 trial, compared patients undergoing colorectal resections with and without drainage. The results showed no significant differences between the groups in terms of clinical AL (8.5% vs. 7.6%; P=0.57), radiologic AL (4.2% vs. 5.6%; P=0.42), and pelvic sepsis (9.7% vs. 10.5%, P=0.75) [41]. Therefore, the routine use of intra-abdominal drainage is currently not recommended.

#### **5. The role of diverting stoma in anastomotic leakage reduction**

While diverting stomas were initially intended to prevent AL and mitigate the severe morbidity associated with AL, their effectiveness in preventing AL remains unconfirmed. Furthermore, the

use of diverting stomas comes with the potential risks of dehydration and complications related to stoma closure [42,43].

A systematic review and meta-analysis, which solely focused on RCTs and included four RCTs with a total of 358 patients, found that the use of diverting stomas significantly diminished the risk of AL (OR=0.32) [44]. A more recent meta-analysis revealed that patients without diverting ileostomies experienced a significantly higher incidence of AL than those with a diversion (OR=0.292; 95% CI, 0.177–0.481) [45]. However, this study also discovered that the rate of complications other than AL was significantly higher in patients with diverting ileostomies than in those without (OR=3.337; 95% CI, 1.570–7.093).

A blow-hole type stoma was proposed as a method to reduce stoma-related complications in certain clinical settings [46]. However, it is not expected to prevent AL or reduce the morbidity associated with AL.

Therefore, in clinical practice, careful consideration of both the benefits and risks associated with diverting stomas is essential.

---

## Conclusion

AL remains a significant concern in colorectal surgery. The method of anastomosis does not appear to be associated with AL, but the use of multiple cartridges in transecting the rectum during rectal surgery could be linked to AL. Several new techniques aimed at reducing cartridge use have been introduced and have shown promising results in small-scale studies. Intraoperative reinforcing sutures have also been effectively utilized to mitigate AL. The application of fluorescence angiography has demonstrated the potential to decrease AL. However, the use of intra-abdominal drains has proven ineffective in preventing AL and thus cannot be recommended. A recent meta-analysis has shown that trans-anal drains can have a positive effect in reducing AL, although the results have been inconsistent. The use of diverting stomas could potentially reduce AL-associated morbidity, but complications related to the stoma must also be considered.

Numerous efforts have been made to reduce AL in colorectal surgery. However, some of these approaches lack high-level evidence to support their effectiveness. To address this, well-designed studies should be conducted to determine the impact of both traditionally used and newly developed techniques in preventing AL. Moreover, the adoption of these techniques should be individualized, taking into account patient-specific risk factors and the clinical settings.

---

## Acknowledgements

Not applicable.

### Conflict of Interest

No potential conflict of interest relevant to this article was reported.

### ORCID iD

Hyun Gu Lee: <https://orcid.org/0000-0001-5736-7645>

### Author Contribution

The article is prepared by a single author.

### Ethics Approval and Consent to Participate

Not applicable.

## References

- Kim MH, Park S, Yi N, Kang B, Park IJ. Colorectal cancer mortality trends in the era of cancer survivorship in Korea: 2000–2020. *Ann Coloproctol* 2022;38(5):343-352.
- Sauer R, Liersch T, Merkel S, Fietkau R, Hohenberger W, Hess C, et al. Preoperative versus postoperative chemoradiotherapy for locally advanced rectal cancer: results of the German CAO/ARO/AIO-94 randomized phase III trial after a median follow-up of 11 years. *J Clin Oncol* 2012;30(16):1926-1933.
- Clinical Outcomes of Surgical Therapy Study Group. A comparison of laparoscopically assisted and open colectomy for colon cancer. *N Engl J Med* 2004;350(20):2050-2059.
- Mody K, Baldeo C, Bekaii-Saab T. Antiangiogenic therapy in colorectal cancer. *Cancer J* 2018;24(4):165-170.
- Park IJ. Precision medicine for primary rectal cancer will become a reality. *Ann Coloproctol* 2022;38(4):281-282.
- Jutesten H, Buchwald PL, Angenete E, Rutegård M, Lydrup ML. High risk of low anterior resection syndrome in long-term follow-up after anastomotic leakage in anterior resection for rectal cancer. *Dis Colon Rectum* 2022;65(10):1264-1273.
- Kim S, Kang SI, Kim SH, Kim JH. The effect of anastomotic leakage on the incidence and severity of low anterior resection syndrome in patients undergoing proctectomy: a propensity score matching analysis. *Ann Coloproctol* 2021;37(5):281-290.
- Koedam TWA, Bootsma BT, Deijen CL, van de Brug T, Kazemier G, Cuesta MA, et al. Oncological outcomes after anastomotic leakage after surgery for colon or rectal cancer: increased risk of local recurrence. *Ann Surg* 2022;275(2):e420-e427.
- Ng JY, Chen CC. Transanal total mesorectal excision for rectal cancer: it's come a long way and here to stay. *Ann Coloproctol* 2022;38(4):283-289.
- Park JW, Kang SB, Hao J, Lim SB, Choi HS, Kim DW, et al. Open versus laparoscopic surgery for mid or low rectal cancer after neoadjuvant chemoradiotherapy (COREAN trial): 10-year follow-up of an open-label, non-inferiority, randomised controlled trial. *Lancet Gastroenterol Hepatol* 2021;6(7):569-577.
- Piozzi GN, Kim SH. Robotic intersphincteric resection for low rectal cancer: technical controversies and a systematic review on the perioperative, oncological, and functional outcomes. *Ann Coloproctol* 2021;37(6):351-367.
- Jayne D, Pigazzi A, Marshall H, Croft J, Corrigan N, Copeland J, et al. Effect of robotic-assisted vs conventional laparoscopic surgery on risk of conversion to open laparotomy among patients undergoing resection for rectal cancer: the ROLARR randomized clinical trial. *JAMA* 2017;318(16):1569-1580.
- Varela C, Nassr M, Razak A, Kim NK. Double-layered hand-sewn anastomosis: a valuable resource for the colorectal surgeon. *Ann Coloproctol* 2022;38(3):271-275.
- Slieker JC, Daams F, Mulder IM, Jeekel J, Lange JF. Systematic review of the technique of colorectal anastomosis. *JAMA Surg* 2013;148(2):190-201.
- Radovanovic Z, Petrovic T, Radovanovic D, Breberina M, Golubovic A, Lukic D. Single versus double stapling anastomotic technique in rectal cancer surgery. *Surg Today* 2014;44:1026-1031.
- Varela C, Kim NK. Surgical treatment of low-lying rectal cancer: updates. *Ann Coloproctol* 2021;37(6):395-424.
- Balciscueta Z, Uribe N, Caubet L, López M, Torrijo I, Tabet J, et al. Impact of the number of stapler firings on anastomotic leakage in laparoscopic rectal surgery: a systematic review and meta-analysis. *Tech Coloproctol* 2020;24(9):919-925.
- Braunschmid T, Hartig N, Baumann L, Dauser B, Herbst F. Influence of multiple stapler firings used for rectal division on colorectal anastomotic leak rate. *Surg Endosc* 2017;31(12):5318-5326.
- Mizuuchi Y, Tanabe Y, Sada M, Tamura K, Nagayoshi K, Nagai S, et al. Cross-sectional area of psoas muscle as a predictive marker of anastomotic failure in male rectal cancer patients: Japanese single institutional retrospective observational study. *Ann Coloproctol* 2022;38(5):353-361.
- Ito M, Sugito M, Kobayashi A, Nishizawa Y, Tsunoda Y, Saito N. Relationship between multiple numbers of stapler firings during rectal division and anastomotic leakage after laparoscopic rectal resection. *Int J Colorectal Dis* 2008;23(7):703-707.
- Lee S, Ahn B, Lee S. The relationship between the number of intersections of staple lines and anastomotic leakage after the use of a double stapling technique in laparoscopic colorectal surgery. *Surg Laparosc Endosc Percutan Tech* 2017;27(4):273-281.
- Chen ZF, Liu X, Jiang WZ, Guan GX. Laparoscopic double-stapled colorectal anastomosis without "dog-ears". *Tech Coloproctol* 2016;20:243-247.
- De Robles MS, John Young C. Triple-staple technique effectively reduces operating time for rectal anastomosis. *Ann Coloproctol* 2021;37(1):16-20.
- Maeda K, Nagahara H, Shibutani M, Ohtani H, Sakurai K, Toyokawa T, et al. Efficacy of intracorporeal reinforcing sutures for anastomotic leakage after laparoscopic surgery for rectal cancer. *Surg Endosc* 2015;29(12):3535-3542.
- Lin H, Yu M, Ye G, Qin S, Fang H, Jing R, et al. Intracorporeal reinforcement with barbed suture is associated with low anastomotic leakage rates after laparoscopic low anterior resection for rectal cancer: a retrospective study. *BMC Surg* 2022;22(1):335.
- Ban B, Shang A, Shi J. Efficacy of staple line reinforcement by barbed suture for preventing anastomotic leakage in laparoscopic rectal cancer surgery. *World J Gastrointest Surg* 2022;14(8):821-832.
- Jiang TY, Zang L, Dong F, Feng B, Zong YP, Sun J, et al. Effect of different reinforcement methods on anastomotic leakage prevention after laparoscopic double anastomosis. *J Surg Oncol* 2021;123(Suppl 1):S81-S87.
- Kim IY, Kim BR, Kim YW. Applying reinforcing sutures to stapled colorectal anastomosis after low anterior resection for rectal cancer. *Eur J Surg Oncol* 2015;41(6):808-809.
- Ryu HS, Lim SB, Choi ET, Song I, Lee JL, Kim CW, et al. Intraoperative perfusion assessment of the proximal colon by a visual grading system for safe anastomosis after resection in left-sided colorectal cancer patients. *Sci Rep* 2021;11(1):2746.

30. Son GM, Ahn H, Lee IY, Ha GW. Multifunctional indocyanine green applications for fluorescence-guided laparoscopic colorectal surgery. *Ann Coloproctol* 2021;37(3):133-140.
31. Alekseev M, Rybakov E, Khomyakov E, Zarodnyuk I, Shelygin Y. Intraoperative fluorescence angiography as an independent factor of anastomotic leakage and a nomogram for predicting leak for colorectal anastomoses. *Ann Coloproctol* 2022;38(5):380-386.
32. Jafari MD, Pigazzi A, McLemore EC, Mutch MG, Haas E, Rasheid SH, et al. Perfusion assessment in left-sided/low anterior resection (PILLAR III): a randomized, controlled, parallel, multicenter study assessing perfusion outcomes with PINPOINT near-infrared fluorescence imaging in low anterior resection. *Dis Colon Rectum* 2021;64(8):995-1002.
33. Shen Y, Yang T, Yang J, Meng W, Wang Z. Intraoperative indocyanine green fluorescence angiography to prevent anastomotic leak after low anterior resection for rectal cancer: a meta-analysis. *ANZ J Surg* 2020;90(11):2193-2200.
34. Kim JC, Lee JL, Park SH. Interpretative guidelines and possible indications for indocyanine green fluorescence imaging in robot-assisted sphincter-saving operations. *Dis Colon Rectum* 2017;60(4):376-384.
35. Crafa F, Striano A, Esposito F, Rossetti ARR, Baiamonte M, Gianfreda V, et al. The "reverse air leak test": a new technique for the assessment of low colorectal anastomosis. *Ann Coloproctol* 2022;38(1):20-27.
36. Aly M, O'Brien JW, Clark F, Kapur S, Stearns AT, Shaikh I. Does intra-operative flexible endoscopy reduce anastomotic complications following left-sided colonic resections? A systematic review and meta-analysis. *Colorectal Dis* 2019;21(12):1354-1363.
37. Ha RK, Han KS, Park SS, Sohn DK, Hong CW, Kim BC, et al. Efficacy and safety of endoscopic clipping for acute anastomotic bleeding after colorectal surgery. *Ann Coloproctol* 2022;38(3):262-265.
38. Shigeta K, Okabayashi K, Baba H, Hasegawa H, Tsuruta M, Yamafuji K, et al. A meta-analysis of the use of a transanal drainage tube to prevent anastomotic leakage after anterior resection by double-stapling technique for rectal cancer. *Surg Endosc* 2016;30(2):543-550.
39. Guo C, Fu Z, Qing X, Deng M. Prophylactic transanal drainage tube placement for preventing anastomotic leakage after anterior resection for rectal cancer: a meta-analysis. *Colorectal Dis* 2022;24(11):1273-1284.
40. Denost Q, Rouanet P, Faucheron JL, Panis Y, Meunier B, Cotte E, et al. To drain or not to drain infraperitoneal anastomosis after rectal excision for cancer: the GRECCAR 5 randomized trial. *Ann Surg* 2017;265(3):474-480.
41. Podda M, Di Saverio S, Davies RJ, Atzeni J, Balestra F, Virdis F, et al. Prophylactic intra-abdominal drainage following colorectal anastomoses. A systematic review and meta-analysis of randomized controlled trials. *Am J Surg* 2020;219(1):164-174.
42. Maeda K. Prolapse of intestinal stoma. *Ann Coloproctol* 2022;38(5):335-342.
43. Kim HS, Kang JH, Kim H, Kim YH, Bae H, Kim NK. Clostridium difficile infection after ileostomy reversal. *Ann Coloproctol* 2021;37(Suppl 1):S4-S6.
44. Hüser N, Michalski CW, Erkan M, Schuster T, Rosenberg R, Kleeff J, et al. Systematic review and meta-analysis of the role of defunctioning stoma in low rectal cancer surgery. *Ann Surg* 2008;248(1):52-60.
45. Ahmad NZ, Abbas MH, Khan SU, Parvaiz A. A meta-analysis of the role of diverting ileostomy after rectal cancer surgery. *Int J Colorectal Dis* 2021;36(3):445-455.
46. Park Y, Choi DU, Kim HO, Kim YB, Min C, Son JT, et al. Comparison of blowhole colostomy and loop ostomy for palliation of acute malignant colonic obstruction. *Ann Coloproctol* 2022;38(4):319-326.